

Three-dimensional ultrasound imaging

Aaron Fenster* and Donal B. Downey

Imaging Research Laboratories, The J.P. Robarts Research Institute
100 Perth Drive, London, Ontario,
CANADA, N6A 5K8

ABSTRACT

The last two decades have witnessed unprecedented developments of imaging systems making use of 3D visualization. These new technologies have revolutionized diagnostic radiology, by providing information about the interior of the human body never before available. Ultrasound imaging is an important cost-effective technique used routinely in the management of a number of diseases. However, technical improvements are needed before its full potential is realized, particularly in applications involving minimally invasive therapy or surgery.

2D viewing of 3D anatomy, using conventional ultrasound, limits our ability to quantify and visualize the anatomy and guide therapy. This occurs because the use of 2D ultrasound requires that the diagnostician integrate multiple images in his mind. This practice is inefficient, and may lead to variability and incorrect diagnoses. Also, the 2D ultrasound image represents a thin plane at an arbitrary angle in the body. It is difficult to localize the image plane, and reproduce it at a later time.

Over the past 2 decades, investigators have addressed these limitations by developing 3D ultrasound techniques. In this paper we describe our developments of 3D ultrasound techniques for imaging organs such as the prostate, breast, and kidney. To produce a 3D image, the ultrasound transducer is scanned mechanically or using a free-hand technique. The images are digitized and then reconstructed into a 3D image, which can be viewed and manipulated interactively. In addition, the user can segment the organ and measure its volume manually or using semi-automatic techniques.

In this paper we describe the use of 3D ultrasound for diagnosis, image-guided therapy and quantifying organ volume. Examples will be given for imaging various organs, such as the prostate, carotid arteries, and breast, and for the use in 3D ultrasound-guided brachytherapy. In addition, we describe 3D segmentation methods that can be used for analysis of the volume of the prostate and carotid vessel lumen using 3D ultrasound images. The segmentation techniques applied to 3D ultrasound images has been shown to be less variable than manual segmentation techniques and of value in both 3D ultrasound-guided prostate brachytherapy and in the assessment of carotid plaque progression/regression.

Keywords: Three-dimensional, 3D imaging, 3D ultrasound, image guided therapy.

1. INTRODUCTION

Three-dimensional visualization of the interior of the human body has been a goal of medical imaging since the discovery of x-rays. Attempts to develop imaging techniques producing 3-dimensional (3D) images of the human body were unsuccessful until the development of CT. In addition to CT, advances in ultrasound (US), PET, and MRI have revolutionized diagnostic radiology, as for the first time, 3D information of the interior of the human body was recorded. However, techniques to visualize the 3D information were slower to develop primarily because of the demanding computational requirements for 3D reconstruction and visualization. Typically, the acquired 3D information was presented as 2D images, requiring the physician to assemble the 3D information in their mind.

* afenster@irus.ri.ca; Phone: (519) 663-3833; fax: (519) 663-3900; <http://www.irus.ri.ca/~afenster>; Imaging Research Laboratories, 100 Perth Drive, London ON, CANADA, N6A 5K8.

Recent advances in computer technology and visualization techniques have allowed real-time reconstruction of 3D images and their visualization and manipulation on inexpensive desktop computers. Only now, can we begin to explore the full potential of true 3D imaging and visualization for both diagnostic and therapeutic applications.

Ultrasound imaging is an important imaging modality available in most hospitals in the world. Over the past 50 years, it has progressed slowly from A-mode systems showing tissue interfaces as an oscilloscope-like trace, to ones producing real-time tomographic images of the anatomy and blood flow. Image quality of medical ultrasound has advanced, making it an indispensable tool in obstetrics and in the diagnosis and management of many diseases. Nevertheless, ultrasound imaging still suffers from several disadvantages related to its 2-dimensional nature, which 3D imaging attempts to address. Despite decades of exploration, it is only in the past five years that 3D ultrasound imaging has advanced sufficiently to move out of the research laboratory and become a commercial product for routine clinical use.

2. 3D US OBJECTIVES

Conventional 2D US is a highly flexible imaging modality, allowing the user to manipulate the transducer and view the desired anatomical section. This flexibility provides an advantage over other medical imaging modalities, but it also results in a major disadvantage that 3D US imaging attempts to address:

- Conventional 2D US provides only one thin image plane of patient at any time, and the location of this image plane is controlled by manually manipulating the transducer orientation. Thus, the user must mentally integrate many 2D US images to form an impression of the 3D anatomy and pathology. This process is time-consuming and inefficient, potentially leading to inaccuracy and variability.
- Placing the 2D US image plane at a particular desired location within an organ, or to find that same location at a later time is difficult. This makes 2D US imaging sub-optimal for planning or monitoring therapeutic procedures, or for performing serial studies of disease progression or regression.
- It is sometimes difficult or impossible to orient the 2D US transducer to obtain the optimal image plane due to the patient's anatomy or position. Manipulation of the 3D US image will allow viewing of an arbitrarily orientated image plane within the data volume.
- Conventional 2D US measurement of organ or lesion volume is usually derived from one or two 2D images and the volume calculated based on an assumed shape. Since selection of the 2D planes is arbitrary and controlled by the user, variable and inaccurate values result. 3D US permits the segmentation of the desired structure in 3D thereby providing more accurate and less variable estimates of volume.

3. BASIC PRINCIPALS OF 3D US

Over the past decade, two approaches have been used to develop 3D US systems: (i) reconstruction of acquired series of 2D images produced by conventional 1D arrays, or (ii) generation of 3D images directly from systems using 2D arrays. Although the 2D array approach would be the most convenient for the operator, this technology is not yet in wide use. Most 3D US systems available today have used conventional ultrasound machines with 1D arrays to acquire 2D images and reconstruct them into 3D US images. Good image quality and avoidance of distortions in the 3D US image requires that two important criteria be met:

- The relative position and orientation of the acquired 2D images must be accurately known so that the reconstructed 3D image is free of artifacts and is not distorted, and,

- Image acquisition must be carried out rapidly and/or gated to avoid artifacts caused by respiratory, cardiac and involuntary motion.

We have developed three approaches for 3D US imaging: untracked freehand, tracked freehand, and mechanical scanning assemblies (Fig 1). In the following sections we briefly describe these approaches and review some important applications. For more detailed descriptions of 3D US approaches, refer to recent review articles and two books.¹⁻⁴

3.1 3D US Scanning Approaches

3.1.1 Untracked free-hand 3D US scanning systems

The operator manually moves the transducer in a steady and regular motion either linearly over the patient's skin, or tilting the transducer with the transducer face fixed on the patient's skin. While the operator is moving the transducer, conventional 2D US images are digitized and stored in a computer memory. A 3D US image is reconstructed by assuming that the acquired images are parallel or angulated to each other and are separated by a constant spatial or angular spacing. Since there is no direct information regarding the actual positions and orientation of the digitized images, the operator must move the transducer at a pre-selected linear or angular velocity to avoid distortions. Because no direct position or orientation information is available, geometric measurements such as distance or volume may be inaccurate and should not be made.

3.1.2 Tracked free-hand 3D US scanning systems

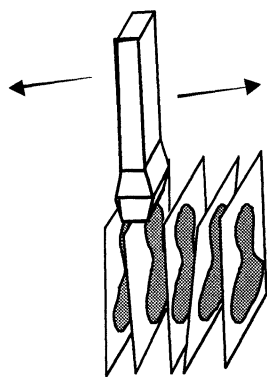
In this approach, the operator holds an assembly composed of the transducer and an attachment that provides information on the position and orientation of the transducer (Fig. 1a). To produce a 3D US image, the operator scans the patient's anatomy in the usual manner, while 2D images along with their position and orientation is recorded. The most common approach for tracking uses a 6-degree-of-freedom magnetic positioning device.⁵ Since 2D images are acquired with arbitrary position and orientation, the geometrical information must be known accurately and precisely for each acquired image, and the operator must ensure that no significant gaps are left between acquired images.

3.1.3 Mechanical 3D US scanning assemblies

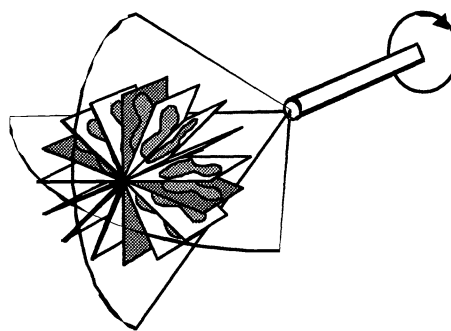
Freehand 3D scanning offers great flexibility, however, distortions, due to noise or miscalibration and scanning gaps may reduce the image quality. The mechanical scanning approach removes these problems by ensuring that the scanning direction is sampled optimally and accurately using the predefined mechanical movement of the transducer.

As a mechanical assembly moves the transducer, 2D US images are acquired into computer memory at predefined spatial or angular intervals. With appropriate setting of scan limits, scan speed and video acquisition rate, the volume of interest can be sampled properly without gaps. Various kinds of mechanical 3D probe assemblies have been developed to be compatible with mechanical or linear-array US transducers. In this approach, the transducer is mounted in the motorized assembly, which rotates or translates the transducer over the region being examined (see Fig. 1). Since the mechanical scanning assembly predefines the scanning geometry, no external frame of reference is necessary and the reconstruction is made efficient by pre-computing the required geometrical parameters.

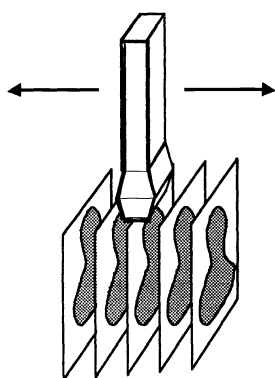
The sizes of the assemblies vary from small integrated mechanisms housing the motor and transducer within the housing; to ones employing a motor attached to a fixture, with an external attachment to the conventional 2D ultrasound transducer. The integrated mechanisms are advantageous since they are small, allowing easier use by the operator. However, the use of these special probes with integrated mechanical scanning mechanisms requires the purchase of a special ultrasound system with the integrated 3D scanning capability. While external assemblies are bulkier, they employ existing US transducers obviating the need to purchase an expensive new ultrasound machine to obtain 3D imaging capability. This approach to 3D US imaging has been implemented with three basic types of motion, as shown schematically in Fig. 1: linear, fan and rotation scanning.⁶⁻¹⁰



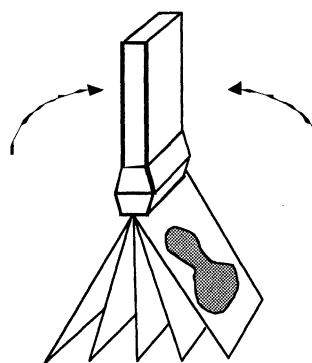
3-D Freehand Scan



3-D Motorized Rotational Scan



3-D Motorized Linear Scan



3-D Motorized Tilt Scan

Figure 1. Schematic diagram showing various approaches to 3D US scanning using conventional 1D ultrasound transducers. a) Free-hand scanning, in which the acquired image planes are acquired with a random position and orientation. b) Mechanical scanning with rotational motion of an end-firing transducer, c) Mechanical scanning with linear motion of the transducer resulting in acquired series of parallel image planes, d) Mechanical scanning with tilting motion, resulting in acquired image planes with a constant angular separation.

3.2 3D US rendering

Many algorithms have been developed to allow users to manipulate 3D images interactively. Although the quality of the 3D US image depends critically on the method of image acquisition and the fidelity of the 3D image reconstruction, the rendering technique used to display the 3D image often plays a dominant role in determining the information transmitted to the operator. Many techniques have been employed in the display of 3D US images, and these can be divided into three broad classes: surface rendering (SR), multi-planar reformatting (MPR), and volume rendering (VR).¹¹⁻¹³

3.2.1 Surface rendering (SR)

The most common 3D display technique used in medical imaging is based on visualizing the surfaces of organs. Because surfaces of the desired structures must first be produced, organ classification and segmentation must first precede the rendering. Organ boundaries can be identified by the operator using manual contouring, or computer-based segmentation techniques. After classification and segmentation steps have been completed, the surfaces are represented by meshes, and then texture mapped with a desired color and texture to represent the anatomical structure.¹¹

Surface rendering approach has been used in 3D US imaging for displaying the fetus, various abdominal structures, and the surfaces of the heart. Since 3D US images suffer from speckle, shadowing and other artifacts observed in 2D US images, classification and segmentation of some structures is difficult. The best results have been obtained for structures surrounded by fluid such as seen in echocardiographic and obstetrical images.¹

3.2.2 Multi-Planar reformatting (MPR)

In the MPR technique, the 3D image is viewed with a utility to allow to extraction of any desired plane or planes from the 3D data set. The extracted planes are then presented to the user with 3D cues to allow comprehension of the 3D geometry. This rendering technique reduces the presentation of the 3D data to a display of 2D information using planar surfaces, which the radiologist can easily understand.

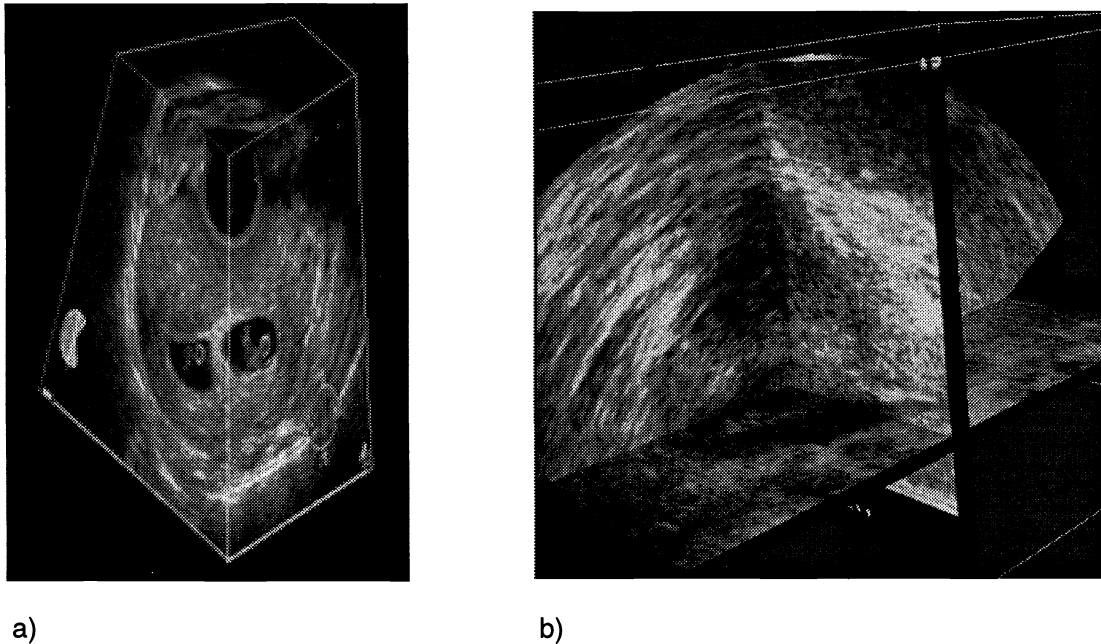


Figure 2. 3D ultrasound images showing the two Multi-planar reformatting approaches: a) cube view approach, in which the extracted planes are texture mapped on the faces of a polyhedron. The 3D US image is of first trimester twins with implantation bleeds. b) Crossed planes view or a prostate, in which the extracted planes are shown intersecting with each other.

Three basic approaches have been used. In the crossed planes (Fig. 2b) the extracted planes are presented in their correct relative orientation. In this viewing approach, the planes are viewed as 2D images, but with cues as to their relationship to the other planes. In the cube-view approach (Fig 2a), the 3D image is presented as a polyhedron and the appropriate ultrasound images are texture-mapped onto the faces. The polyhedron or the crossed plane view can be rotated to obtain the desired orientation of the 3D image. The faces or the extracted planes can then be moved parallel to the original, or reoriented obliquely, while the appropriate ultrasound data is texture-mapped in real-time on the new view. In this way, the operator always has 3D image-based cues relating the plane being manipulated to the rest of the anatomy.

3.2.3 Volume Rendering Techniques (VR)

Although the MPR technique provides 3D cues to the user, it only allows a small part of the complete 3D information to be viewed at any time. An alternative viewing technique uses volume-rendering, which presents a view of the entire 3D image after it has been projected onto a 2D plane. The most common approach uses ray-casting techniques to project a 2D array of rays through the 3D image.^{11,12} Each ray intersects the 3D image along a series of voxels, which can be weighted and then summed in various ways to produce the desired effect. Common approaches in 3D US have been: maximum intensity projection, translucency rendering and surface enhancement as shown below.

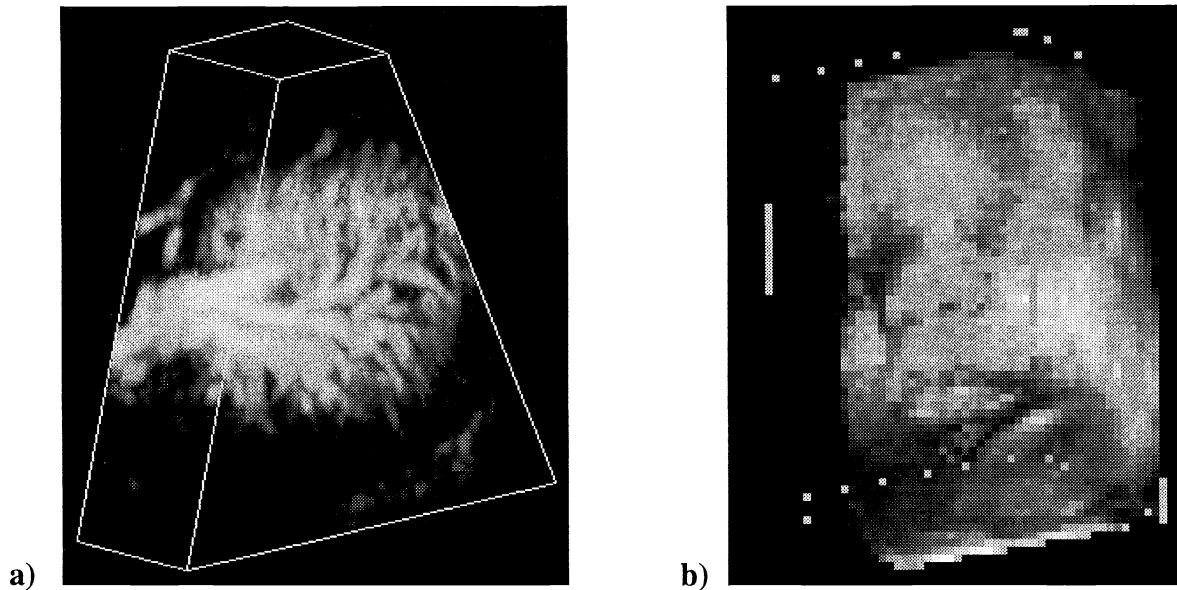


Figure 3. 3D ultrasound images showing two volume rendering approaches of 3D US images. a) Volume rendering using maximum intensity projection of a power Doppler image of a human spleen. b) Volume rendering with enhancement of surfaces of the face of a fetus.

Since the VR technique projects 3D information onto a 2D plane, interpretation of some US rendering may be difficult. Therefore, this approach is best suited for images of simple structures in which anatomical surfaces are clearly distinguishable (fetal face surrounded by amniotic fluid as in Fig. 3b) or for images in which clutter is not present or has been removed (power or colour Doppler images with the B-mode data removed as in Fig. 3a). Successful uses have been demonstrated by investigators, particularly in displaying fetal¹³⁻¹⁵ and vascular anatomy.¹⁶

4. APPLICATIONS

4.1 Prostate cancer and early-stage disease management

The prostate-specific antigen (PSA) blood test has become well established for early detection of prostate cancer, and for monitoring of prostate cancer particularly after treatment.¹⁷ The wide availability of the PSA test, the public's increased awareness about prostate cancer, and the growing number of men approaching the age of 50, have all combined to increase the proportion of prostate cancer diagnosed at an early-stage. Managing and treating these increasingly early stage cancers has generated a great deal of debate in both the medical community and the public. The standard treatment regimens for prostate cancer are: watchful waiting, radical prostatectomy, external beam radiation, and brachytherapy. While watchful waiting is appropriate for some, the majority of men diagnosed with early stage cancer will request or need treatment. There is a growing belief that aggressive therapy may not be justified for early stage disease due to the morbidity (incontinence and impotence) of radical prostatectomy. External beam radiation is effective, but requires long treatment times and results in irradiation of normal tissues.¹⁸ Conformal radiation therapy of the prostate may reduce this problem, however, early reports are mixed. In addition, costs are high in treating and managing patients undergoing these traditional forms of therapy.

In the past 10 years improvements in imaging technology, computer aided dosimetry, and new treatment options have stimulated investigators to search for alternative approaches such as minimally invasive therapies for localized prostate cancer, *e.g.*, brachytherapy, cryosurgery, hyperthermia, interstitial laser photocoagulation (ILP), and photodynamic therapy

(PDT). Of these techniques, brachytherapy is the most advanced and is now considered to be the definitive treatment option for early stage prostate cancer.

4.2 3D Transrectal ultrasound guided permanent implant prostate brachytherapy

Prostate brachytherapy is a form of radiation therapy in which about 80 radioactive seeds (*e.g.*, ^{125}I) are placed directly into the prostate, either temporarily or permanently.^{19,20} Because the control rates of prostate cancer appear to be dose dependent, it is theorized that the higher doses produced by brachytherapy will yield higher control rates than external-beam radiation without a rise in complications. Brachytherapy literature suggests that it has a role in the treatment of early-stage prostate cancer, and also that it may be comparable or even preferable to surgery and external-beam radiation in some patients when evaluated by current therapeutic and economic endpoints.²¹

While removable implant techniques are being developed and used in some institutions, the most common form of brachytherapy involves implanting the sources permanently in the prostate. In either technique, in order to deliver a high conformal dose safely to the prostate, radioactive sources must be positioned accurately within the gland.^{22,23}

Currently, the most common approach makes use of CT- or ultrasound-based pre-implantation dose plan to determine the total activity and distribution of the radioactive seeds in the prostate. At a later patient visit, the seeds are implanted on an outpatient basis under general or spinal anesthesia, while the patient is placed in the “same” lithotomy position as the pre-plan. This procedure is now carried out under transrectal US (TRUS) guidance, but some institution use fluoroscopy. At a separate patient visit after the implantation, the actual seed locations are determined with CT or fluoroscopy and a post-implantation plan is generated.

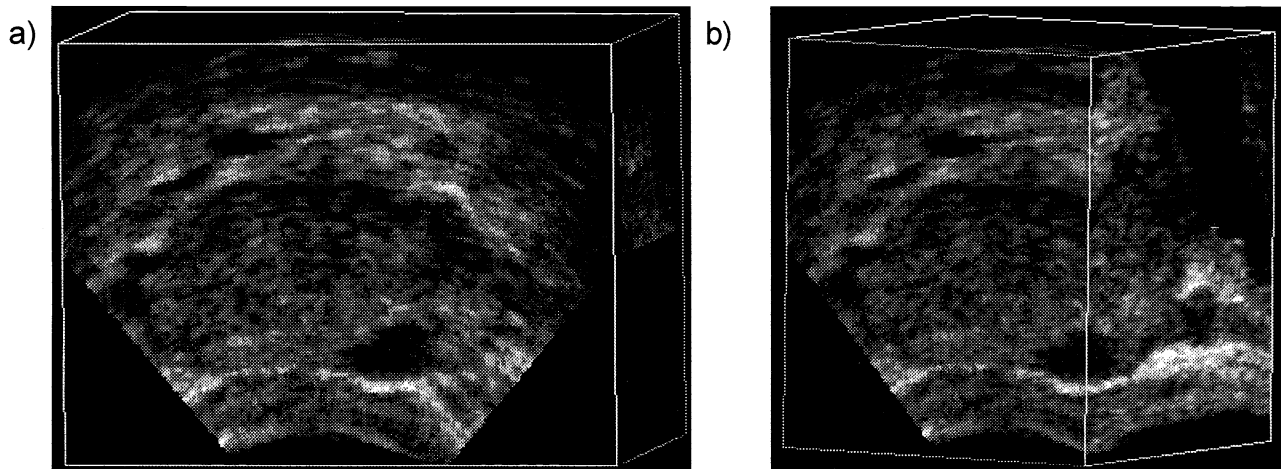


Figure 4. 3D TRUS image of a patient with prostate carcinoma. The 3D image is being rotated and “sliced” using the MPR approach, with the faces of the polyhedron oriented and positioned to display the pathology in the prostate.

The ability to rapidly scan the prostate and then view it in 3D using 3D US^{9,10} has stimulated investigators to consider performing the procedure intra-operatively without a CT-based preplan. This has given the impetus to the development of a complete intra-operative 3D TRUS-guided brachytherapy system.²⁴ This type of approach permits planning and implantation at the same session thereby avoiding problems of repositioning, prostate motion, prostate size/contour changes, and image registration between modalities. This approach also permits the development of post-implant verification, allowing immediate corrections of errors in implantation. However, an intra-operative system requires the integration of the planning software with semi-automatic prostate contouring, needle and seed detection algorithms and real-time comparisons to the preplan.

In the past few years we focused on the development of a 3D ultrasound imaging technique for the diagnosis of prostate cancer^{7,9,10} and have extended its use for prostate cryosurgery.^{25,26} More recently, we have focused on extending our 3D TRUS developments to the use of 3D US imaging in prostate brachytherapy. Our goal is to develop and validate a 3D ultrasound imaging system allowing all aspects of the procedure to be carried out intra-operatively accurately and consistently in one session, including: semi-automated prostate margin and volume definition, real-time 3D implant guidance, verification of needle placement, post-implant radioactive seed deposition verification, as well as long-term follow up at later sessions.

4.3 Prostate segmentation

Shadowing and speckle in ultrasound images make local image processing operators like edge and texture operators inadequate for finding the prostate. The use of neural nets for prostate segmentation is also not optimal because they are slow and require extensive teaching sets. Contour-based methods, such as the “snakes”, show promise but their implementation is complex and sensitive to the initial choice of contour. Our approach²⁷ uses model-based initialization and the efficient Discrete Dynamic Contour (DDC) for boundary refinement.²⁸ Details of our technique have been described in detail elsewhere,²⁷ and are only summarized here.

The DDC is a sequence of points connected by straight-line segments, which deforms to fit the desired boundary.^{27,28} The use of the DDC to segment an object requires an initialization step, in which an approximate outline of the object is generated. After an initial outline is provided, it is automatically deformed to fit the desired features, generally consisting of edges defining the boundary of the prostate.

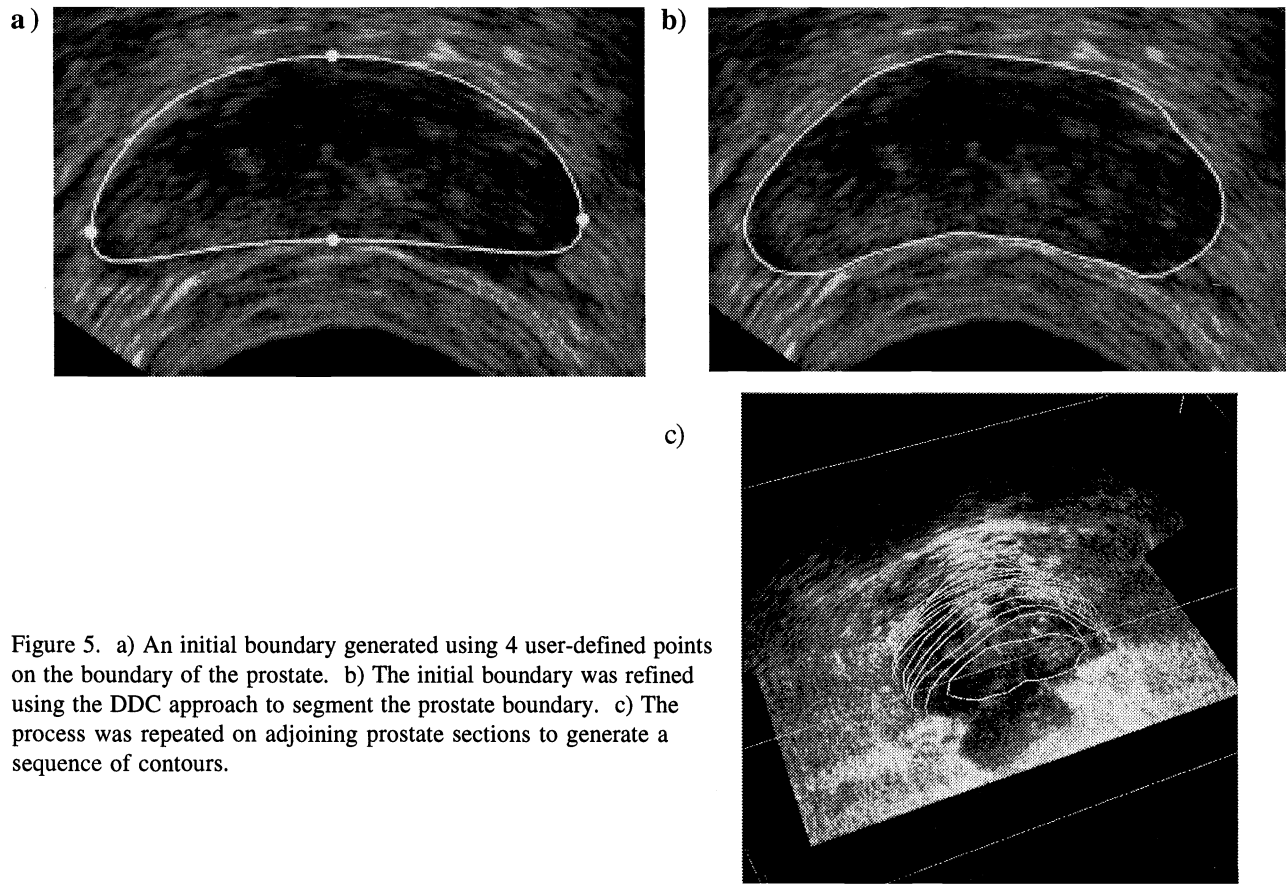


Figure 5. a) An initial boundary generated using 4 user-defined points on the boundary of the prostate. b) The initial boundary was refined using the DDC approach to segment the prostate boundary. c) The process was repeated on adjoining prostate sections to generate a sequence of contours.

Initialization: In the initialization step, the operator selects 4 points on the boundary of the prostate in a transverse 2D image, 2 in the midline defining an axis of symmetry and two at both sides of the base defining the width. These points are then be used to calculate the initial boundary based on a pre-computed model equation of the prostate. Figure 5a shows an example of an initial boundary superimposed on a prostate US image.

Refinement: The initial 2D contour is decomposed into a set of vertices connected by edge vectors. The spacing between vertices is defined by the user, but is typically set at 15 pixels. The initial boundary evolves to minimize the total force by balancing internal and external forces acting on each vertex. The external force at each vertex is proportional to the local image gradient and the internal forces mimic elastic forces and are proportional to edge length. Figure 5b shows the result of the boundary refinement superimposed on the prostate image, demonstrating good segmentation. To segment the complete prostate, this boundary is then used to initialize adjacent image slices, until the complete prostate is segmented as shown in Fig. 5c.

5. CONCLUSIONS

We reported on our development of a 3D ultrasound imaging system for a variety of applications. The 3D system can interface to any conventional ultrasound machine and can accommodate to a variety of ultrasound transducers. After acquiring a series of 2D ultrasound images, a 3D image is reconstructed and viewed interactively with 3D visualization software. These approaches allow physicians to diagnose disease, measure volumes accurately, and plan and guide minimally invasive procedures.

ACKNOWLEDGEMENTS

The authors gratefully acknowledge the financial support of the Canadian Institutes of Health Research, Life Imaging Systems, and the Ontario R & D Challenge Fund.

REFERENCES

1. Nelson TR, Downey DB, Pretorius DH, Fenster, A. *Three-Dimensional Ultrasound*. Lippincott, Williams, and Wilkins, Philadelphia, 1999.
2. Fenster A, Downey DB, "3-D ultrasound imaging: A review". *IEEE Engineering in Medicine and Biology* **15**:41-51, 1996.
3. Fenster A., Downey D., Cardinal N. "Review: 3-dimensional Ultrasound Imaging". *Physics in Medicine and Biology* **46**:R67-R99, 2001.
4. Fenster A, Downey D, "Three-Dimensional Ultrasound Imaging". *Handbook of Medical Imaging, Volume I, Physics and Psychophysics*. Beutel J, Kundel H, Van Metter R (eds.). SPIE Press, Bellingham, Washington, p. 433-509, 2000.
5. Sherebrin S, Fenster A, Rankin R, Spence JD, "Freehand three-dimensional ultrasound: implementation and applications". *SPIE Physics of Medical Imaging* **2708**:296-303, 1996.
6. Picot PA, Rickey DW, Mitchell R, Rankin RN, Fenster A, "Three-dimensional colour Doppler imaging". *Ultrasound in Med & Biol* **19**:95-104, 1993.
7. Tong S, Downey DB, Cardinal HN, Fenster A, "A three-dimensional ultrasound prostate imaging system". *Ultrasound Med Biol* **22**:735-46, 1996.
8. Fenster A, Tong S, Sherebrin S, Downey DB, Rankin RN, "Three-dimensional ultrasound imaging". *SPIE* **2432**:176, 1995.
9. Tong S, Cardinal HN, Downey DB, Fenster A, "Analysis of Linear, Area, and Volume Distortion in 3D Ultrasound Imaging". *Ultrasound in Medicine and Biology*, **24**:355-373, 1998.
10. Cardinal N, Gill J, Fenster A, "Analysis of geometrical distortion and statistical variance in length, area, and volume in a linearly scanned 3D ultrasound image". *IEEE Transactions on Medical Imaging*, **19**, 632-651, 2000.
11. Robb RA, *Three-dimensional biomedical imaging: Principles and practice*. VCH Publishers, New York, 1995.

12. Levoy M, "Volume rendering, a hybrid ray tracer for rendering polygon and volume data". IEEE Computer Graphics and Applications **10**:33-40, 1990.
13. Nelson TR, Pretorius DH, Sklansky M, Hagen-Ansert S, "Three-dimensional echocardiographic evaluation of fetal heart anatomy and function: Acquisition, Analysis, and Display". J Ultrasound Med **15**:1-9, 1996.
14. Pretorius DH, Nelson TR: "Fetal face visualization using three-dimensional ultrasonography". J Ultrasound Med **14**:349-356, 1995.
15. Nelson TR, Pretorius DH: "Visualization of the fetal thoracic skeleton with three-dimensional sonography: A preliminary report". AJR **164**:1485-1488, 1995.
16. Downey DB, Fenster A: "Vascular imaging with a three-dimensional power Doppler system". AJR **165**:665-668, 1995.
17. Kirby RS, "Pre-treatment staging of prostate cancer: recent advances and future prospects". Prostate Cancer and Prostatic Diseases **1**:2-10, 1997.
18. Litwin MS, "Health-related quality of life after treatment of localized prostate cancer". Cancer **75**:2000-2003, 1995.
19. Sylvester J, Blasko JC, Grimm P, Radge H, "Interstitial implantation techniques in prostate cancer". Journal of Surgical Oncology **66**:65-75, 1997.
20. Nag S, *Principles and practice of brachytherapy*. Futura Publishing Company, Inc., Armonk, New York, 1997.
21. Stokes SH, Real JD, Adams PW, Clements JC, Wuertzer S, Kan W, "Transperineal ultrasound-guided radioactive seed implantation for organ-confined carcinoma of the prostate". Int J Radiat Oncol Biol Phys **37**:337-341, 1997.
22. Pouliot J, Tremblay D, Roy J, Filice S, "Optimization of permanent 125I prostate implants using fast simulated annealing". Int J Radiat Oncol Biol Phys **36**:711-720, 1996.
23. Prestidge BR, Hoak DC, Grimm PD, Ragde H, Cavanagh W, Blasko JC: "Posttreatment biopsy results following interstitial brachytherapy in early-stage prostate cancer". Int J Radiat Oncol Biol Phys **37**:31-39, 1997.
24. Blake, C., Elliot, T., Slomka, P., Downey, D., Fenster, A. "Variability and Accuracy of Measurements of Prostate Brachytherapy Seed Position *in vitro* using Three Dimensional Ultrasound: An Intra- and Inter-Observer Study". Medical Physics, **27**:2788-2795, 2000.
25. Chin JL, Downey DB, Onik G, Fenster A, "Three-dimensional prostate ultrasound and its application to cryosurgery". Tech Urol **2**:187-193, 1996.
26. Chin JL, Downey DB, Mulligan M, Fenster A, "Three-dimensional transrectal ultrasound guided cryoablation for localized prostate cancer in nonsurgical candidates: A feasibility study and report of early results". J of Urology **159**:910-914, 1998.
27. Ladak H, Mao F, Wang Y, Downey D, Steinman D, Fenster A, "Prostate Boundary Segmentation from 2D Ultrasound Images". Medical Physics, **27**:1777-1788, 2000.
28. Lobregt S, Viergever MA, "A discrete dynamic contour model," IEEE Trans in Med. Imaging, **14**:12-24 (1995).