

Noninvasive cerebral blood volume measurement during seizures using multichannel near infrared spectroscopic topography

Eiju Watanabe

Tokyo Metropolitan Police Hospital
Department of Neurosurgery
102 Tokyo, Japan

Atsushi Maki

Hitachi Central Research Laboratory

Fumio Kawaguchi

Hitachi Medical Corporation

Yuichi Yamashita

Hideaki Koizumi

Hitachi Central Research Laboratory

Yoshiaki Mayanagi

Tokyo Metropolitan Police Hospital
Department of Neurosurgery
102 Tokyo, Japan

Abstract. Near infrared spectroscopic topography (NIRS) is widely recognized as a noninvasive method to measure the regional cerebral blood volume (rCBV) dynamics coupled with neuronal activities. We analyzed the rCBV change in the early phase of epileptic seizures in 12 consecutive patients with medically intractable epilepsy. Seizure was induced by bemegride injection. We used eight-channel NIRS in nine cases and 24 channel in three cases. In all of the cases, rCBV increased rapidly after the seizure onset on the focus side. The increased rCBV was observed for about 30–60 s. The NIRS method can be applied to monitor the rCBV change continuously during seizures. Therefore, this method may be combined with ictal SPECT as one of the most reliable noninvasive methods of focus diagnosis. © 2000 Society of Photo-Optical Instrumentation Engineers. [S1083-3668(00)00103-9]

Keywords: near infrared spectroscopy; functional mapping; epilepsy; human; hemoglobin; cerebral blood volume.

Paper JBO-915 received Mar. 8, 1999; revised manuscript received June 25, 1999 and Oct. 19, 1999; accepted for publication Nov. 22, 1999.

1 Preface

Recent technological developments such as (PET) and (MEG) have improved the diagnosis for the epileptogenic foci. Interictal PET has been widely accepted as a noninvasive method for focus detection referring to the hypometabolism or hypoperfusion on the focus side. In addition, ictal SPECT which shows hyperperfusion during the seizure has come to be used more frequently.^{1–4} Near-infrared spectroscopy (NIRS) is a new method to measure regional cerebral blood volume (rCBV) noninvasively in daily conditions. Previously we reported that this method can be utilized for measuring brain activities during finger tapping task. It clearly showed the localized rCBV increase in the pericentral cortex.⁵ We have applied this method to the focus diagnosis in the patients with medically intractable epilepsy.

2 Cases and Methods

Twelve cases with medically intractable epilepsy (five males and seven females, aged between 8 and 45) underwent the NIRS measurements. The final diagnosis of the seizure focus was made mainly based on the intracranial (EEG) recordings. The focus was located in the temporal lobe in 10 cases and in the parietal cortex in two.

The hardware setup of NIRS recording is illustrated in Figure 1. Laser diodes with the wavelengths of 780 and 840 nm were used as light sources.^{1,5} Intensity of the near infrared light was modulated in several driving frequencies to suppress the cross talk between the channels and to separate the signal of two wavelengths in each channel. The infrared light was

guided to the scalp surface through an optical fiber bundle (2 mm in diameter). The reflection of infrared light was received by a probe placed on the scalp 30 mm away from the transmitting probe and was guided to a silicon photodiode by an optical fiber. Signal intensities of the near-infrared light of the two wavelengths for each channel were separated and analyzed to obtain the relative change of total hemoglobin concentration in the brain tissue.⁶

For each subject, a shell was made of thermoplastic splint. The NIRS probes were mounted on the shell so as to cover the prospective focus region. Eight channels (four channels on each side) were applied in nine patients and 24 channels (12 on each side) in the three latest cases (cases 9, 10, and 12).

The scalp hair considerably absorbs the infrared light. It interferes with the NIRS measurement if crossing over the light pathway. The diameter of the probe tip was made 2 mm to keep the tip contact directly with the scalp avoiding the hair from crossing over the light pathway. This makes it possible to apply the NIRS even in the haired region.

For ictal measurement, the epileptic seizure was induced as follows. Under the video-EEG monitoring, 0.5 mg/kg of bemegride was injected intravenously, followed by repetitive injections (in every 10 s) of 5 mg of bemegride until the epileptic spike burst was observed. HMPAO was intravenously injected immediately after a spike burst appeared on EEG. The seizure onset time was confirmed by intracranial EEG. SPECT was taken after suppressing seizures with diazepam injection. NIRS measurement was done throughout the course of seizure induction at a rate of 2 s along with intracranial EEG. The changes of Hb concentration before and after the seizure onset were evaluated by *t*-test. The time windows were set from 30 to 20 s before the EEG-seizure onset

This paper was originally scheduled to appear in the October 1999 special section on Medical Near-Infrared Spectroscopy, but was not available in time. Address all correspondence to E. Watanabe. Tel: +81-3-3263-1371; ext. 2542; Fax: +81-3-3263-1291; E-mail: eiju-ind@umin.ac.jp

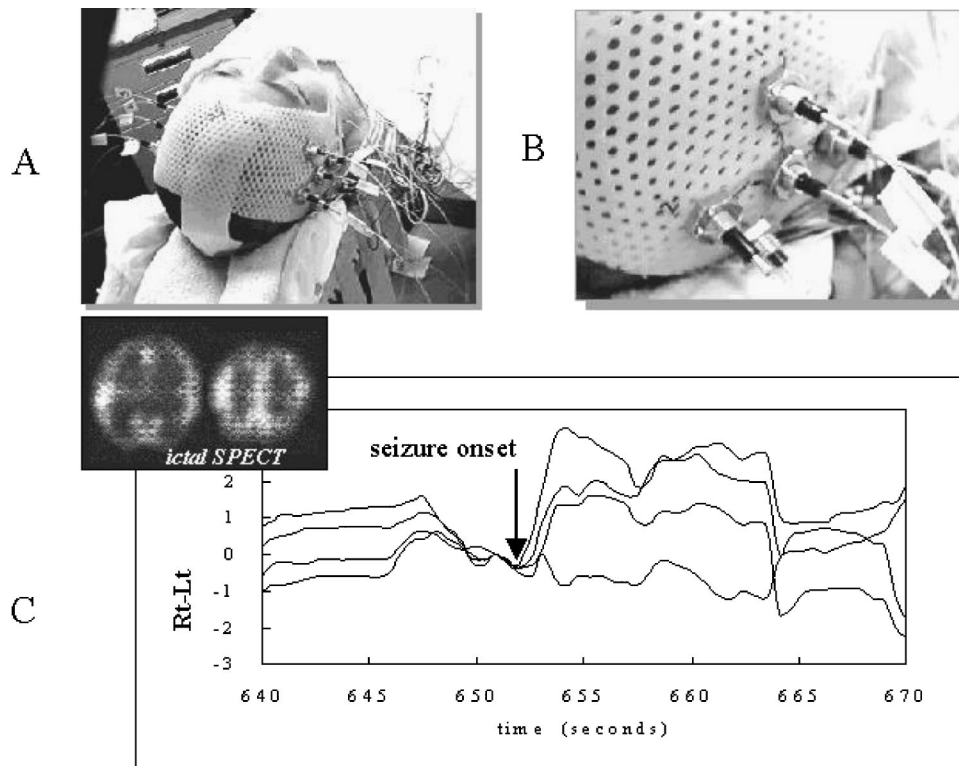


Fig. 1 Eight-channel NIRS mapping was done along with HMPAO-SPECT. (A) The probes were mounted on the head shell covering the area of suspected focus. (B) Their close-up. C-inset: Ictal SPECT. (C) The time course of total hemoglobin concentration around the seizure onset in temporal lobe epilepsy (case 4). Abscissa; the left NIRS data was subtracted from the right. Ordinate; seconds after the bemegride injection. Note that the total hemoglobin increased just after the seizure onset and returned to the resting level within 16 s.

and from 10 to 20 s after the onset, which generated 20 data for each time window. This pair of data was compared by *t*-test and a significant blood volume increase was determined when it showed $p < 0.001$ significance.

Because of the load to the patients, the seizure induction procedure was done only once for a patient.

3 Results

Three representative cases listed in the Table 1 are described below.

Case 4: A 40-year-old female with intractable complex partial epilepsy underwent ictal SPECT along with NIRS monitoring. Eight-channel NIRS measurement (four on each side, symmetrically) was done with 10 probes implanted on the head shell [Figures 1(A) and 1(B)]. Seizure activity was observed by depth EEG recorded with depth electrodes implanted in the right hippocampus. After the seizure onset, the rCBV increased in the right temporal region, lasting for 30 s and returning to the resting level [Figure 1(C)]. Ictal SPECT (Figure 1, inset) showed rCBV increase in the right temporal lobe, compatible to the NIRS findings. A seizure focus was confirmed in the right medial temporal lobe by depth EEG recordings. The right temporal lobectomy was done, releasing her from seizures.

Case 12: An 8-year-old girl with intractable epilepsy was transferred to our clinic for surgical intervention. Her seizure started with tingling sensation in the right arm sometimes fol-

Table 1 Cases with intractable epilepsy studied with NIRS and ictal SPECT. The columns named "EEG," ictal "SPECT," and "NIRS" indicate the side (R: right; L: left; N: not definite) of the side of suspected focus in each modality. "sg channels" indicates a number of channels that showed significant rCBV increase during seizures.

Case	Age	Sex	Focus	EEG	Ictal SPECT	NIRS	Total channels	sg channels
1	45	m	TEMPORAL	R	N	R	8	2
2	19	f	TEMPORAL	L	N	L	8	4
3	27	m	TEMPORAL	L	L	L	8	4
4	40	f	TEMPORAL	R	R	R	8	2
5	40	m	TEMPORAL	L	L	L	8	3
6	25	f	TEMPORAL	L	L	L	8	2
7	25	m	TEMPORAL	R	R	R	8	2
8	20	f	TEMPORAL	R	L	R	8	3
9	21	m	TEMPORAL	L	N	L	24	5
10	28	f	TEMPORAL	L	N	L	24	7
11	27	f	PARIETAL	R	R	R	8	3
12	8	f	PARIETAL	L	L	L	24	4

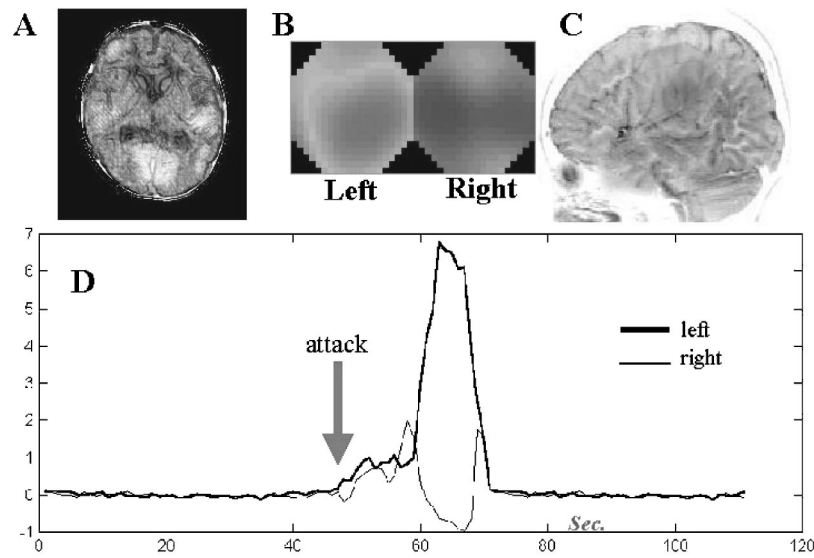


Fig. 2 20 four-channel NIRS mapping during a seizure of the left parietal epilepsy. Seizure began at 48 s after bemegride injection. (A) Ictal SPECT showing hyperperfusion in the left postcentral area. (B) NIRS mapping at 65 s after bemegride Hb total increased in the area corresponding to the ictal SPECT finding. (C) The NIRS mapping on the left was overlaid on the MRI surface image. (D) Time course of [Hb total] at the focus site and its control on the opposite side. A letter at the left of each column indicates the time after bemegride injection. The rCBV began to increase 5 s after spike discharge (at 48 s) in the left parietal area.

lowed by secondary generalization. Under EEG and NIRS monitoring, a seizure was induced with bemegride injection. A seizure began in the left parietal area. Ictal SPECT showed the hyperperfusion in the left postcentral area [Figure 2(A)]. NIRS showed rCBV increase in the same area as that in ictal SPECT immediately after the seizure onset lasting for about 25 s [Figures 2(B) and 2(C)]. Figure 2(D) shows the time courses of [Hb total] at the focus site and its counterpart on the opposite side. A letter at the left of each column indicates the time after bemegride injection. The rCBV began to increase 5 s after spike discharge (at 48 s) in the left parietal area. The subdural electrodes demonstrated the seizure spike onset in the left postcentral area which supported the above

findings. The small corticectomy (20 mm by 20 mm in size) was done in the left postcentral area resulting in 80% seizure reduction after the surgery.

Case 11: This is a 27-year-old female with medically intractable epilepsy. Her seizures usually began with simple partial seizures with tingling sensation in her right arm, followed by clonic seizures of her right arm. Secondary generalizations were sometimes observed. MRI revealed T2-high area in the left postcentral gyrus, suggesting cortical dysplasia (Figure 3 insets). MEG showed spike dipoles gathering in the abnormal area in MRI. The video-EEG monitoring showed that spike burst discharges began in the left central area before the clinical seizures. Ictal SPECT was performed with NIRS.

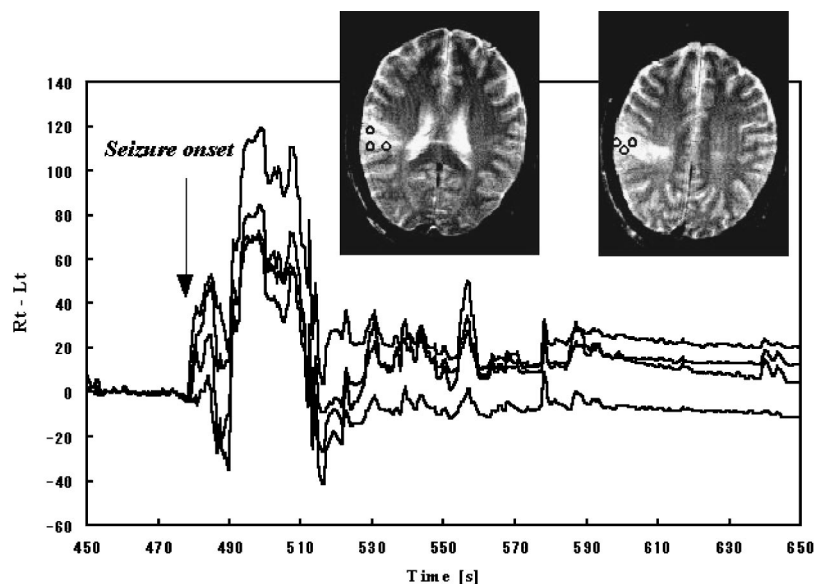


Fig. 3 NIRS and MEG of Case 11. Upper insets: circles represent the spike dipoles by MEG, which are overlapped on MRI. Lower; eight-channel NIRS mapping during a seizure. Steep rCBV increase was noted after the seizure onset. The rCBV returned to the resting level in 30 s.

The NIRS probes were placed on bilateral postcentral areas covering the region with abnormal MRI. A seizure occurred with the EEG and clinical patterns similar to the habitual ones after bemegride injection. The ictal SPECT showed a hyperperfusion area in the left postcentral region compatible to the MRI and MEG findings. The NIRS recording showed a steep increase of rCBV in the left postcentral area immediately after the EEG spike train onset (Figure 3). The increased rCBV remained for 30 s and returned to the preictal state. Subdural grid electrodes revealed spike bursts beginning in the left postcentral area prior to the clinical seizures.

The above findings suggested the focus in the left postcentral gyrus. The parietal region including the focus was resected making the patient almost freed from seizures.

4 Summary of Cases

The results of NIRS measurement in 12 cases are summarized in the Table 1. The seizure foci were confirmed by the EEG and MRI findings. Ictal NIRS were measured along with the ictal SPECT in all the cases. Ictal SPECT demonstrated distinct hyperperfusion in the areas surrounding the seizure foci in seven cases, whereas no obvious hyperperfusion was found in four cases and one showed an increase on the contralateral side. The NIRS demonstrated rCBV increase in the region of the focus in all the cases. The increase began within 2–5 s after the seizure onset confirmed by intracranial EEG, and it lasted for 45+12.3 s. In cases 9 and 10, rCBV increase began on the focus side and spread to the other side within 10 s.

5 Discussion

The near infrared light projected into the brain penetrates and reflects randomly in the tissue.⁷ The near infrared light measured at a certain distance represents the absorption by quasiseismic tissue in the brain connecting the transmitting and the receiving probes. The depth of the measuring point depends on the distance between the transmitting and receiving probes. It was reported that NIRS signal mainly reflected the absorption at the depth of 1.2–2.0 cm below the scalp when the interprobe distance was 27 mm.⁷ As the human cerebral cortex usually lies about 10–20 mm below the scalp, the appropriate interprobe distance should be 25–30 mm to measure the activities in the superficial cortex. The interprobe distance was therefore determined as 30 mm in the present study.

The tight coupling between the neuronal activity and the rCBV increase has been established⁸ and used in the functional mapping with PET, SPECT, and fMRI. Watanabe et al.⁵ reported that the rCBV increase was demonstrated by NIRS in the pericentral region during finger tapping task. The activity-coupled rCBV increase is also expected during epileptic seizures. Horsley first described ictal focal hyperperfusion by the direct visual inspection of the brain during seizures. The PET unexpectedly taken during seizures confirmed this. Ictal SPECT is the first well-planned examination to reveal the ictal hyperperfusion. Rowe et al.,² Newton et al.,^{1,9,10} and Stefan et al.³ described the ictal hyperperfusion by

HMPAO-SPECT. They demonstrated obvious hyperperfusion in epileptogenic area when HMPAO was injected during a seizure or within 30 s after the seizure termination. In this study, we observed compatible ictal rCBV increase also with NIRS method.

It should be noted that NIRS measures only the phenomenon in the superficial cortex of the brain making it ideal for neocortical epilepsy. It is particularly important when we evaluate the results in medial temporal epilepsy. Ictal SPECT demonstrated that, in most of the cases with medial temporal epilepsy, rCBV increased in the ipsilateral lateral temporal cortex as well as in the medial temporal structures⁴ supposedly according to the seizure spread to these areas. The seizure spread is usually detectable only by intracranial subdural electrode EEG but not by scalp EEG. This supports the feasibility of the NIRS and its advantage over scalp EEG even in the medial temporal epilepsy.

6 Conclusion

In search for noninvasive methods for focus diagnosis, we reached a conclusion that the combination of ictal SPECT and NIRS is one of the most reliable techniques to visualize the hemodynamic changes during seizures. The ictal SPECT offers the static tomographic images of rCBV and the NIRS enables us to observe the rCBV continuously. If combined, these two methods may support each other.

References

1. M. R. Newton, S. F. Berkovic, M. C. Austin, C. C. Rowe, W. J. McKay, and P. F. Bladin, "Ictal postictal and interictal single-photon emission tomography in the lateralization of temporal lobe epilepsy," *Eur. J. Nucl. Med.* **21**, 1067–1071 (1994).
2. C. C. Rowe, F. S. Berkovic, S. T. B. Sia, M. Austin, W. J. McKay, R. M. Kalnins, and P. F. Bladin, "Localization of epileptic foci with postictal single photon emission computed tomography," *Ann. Neurol.* **26**, 660–668 (1989).
3. H. Stefan, J. Bauer, and H. Feistel, "Regional cerebral blood flow during focal seizures or temporal and frontocentral onset," *Ann. Neurol.* **27**, 162–166 (1990).
4. E. Watanabe and Y. Mayanagi, "Ictal SPECT in temporal and extratemporal epilepsy," *Epilepsia* **38**, 48–53 (1997).
5. E. Watanabe, Y. Yamashita, A. Maki, Y. Ito, and H. Koizumi, "Non-invasive functional mapping with multichannel near infrared spectroscopic topography in humans," *Neurosci. Lett.* **205**, 41–44 (1996).
6. A. Maki, Y. Yamashita, Y. Ito, and H. Koizumi, "Spatial and temporal analysis of human motor activity using noninvasive NIR topography," *Med. Phys.* **22**, 1997–2005 (1996).
7. P. W. McCormick, M. Stewart, G. Lewis, M. Dujovny, and J. I. Ausman, "Intracerebral penetration of infrared light technical note," *J. Neurosurg.* **76**, 315–318 (1992).
8. E. Leininger-Follert and K. A. Hossmann, "Simultaneous measurements of microflow and evoked potentials in the somatosensory cortex of the cat during specific sensory activation," *Pfluegers Arch* **380**, 85–89 (1979).
9. M. R. Newton, S. F. Berkovic, M. C. Austin, C. C. Rowe, W. J. McKay, and P. F. Bladin, "SPECT in the localization of extratemporal and temporal seizure foci," *J. Neurol. Neurosurg. Psychiatry* **59**, 26–30 (1995).
10. S. S. Ho, S. Berkovic, M. R. Newton, M. C. Austin, W. J. McKay, and P. F. Bladin, "Parietal lobe epilepsy: Clinical features and seizure localization by ictal SPECT," *Neurology* **44**, 2277–2284 (1994).