

Efficacy of laser phototherapy in comparison to topical clobetasol for the treatment of oral lichen planus: a randomized controlled trial

Caroline Siviero Dillenburg
Marco Antonio Trevizani Martins
Maria Cristina Munerato
Márcia Martins Marques
Vinícius Coelho Carrard
Manoel Sant'Ana Filho
Rogério Moraes Castilho
Manoela Domingues Martins

Efficacy of laser phototherapy in comparison to topical clobetasol for the treatment of oral lichen planus: a randomized controlled trial

Caroline Siviero Dillenburg,^a Marco Antonio Trevizani Martins,^b Maria Cristina Munerato,^b Márcia Martins Marques,^c Vinícius Coelho Carrard,^a Manoel Sant'Ana Filho,^a Rogério Moraes Castilho,^d and Manoela Domingues Martins^{a,*}

^aUniversidade Federal do Rio Grande do Sul, School of Dentistry, Department of Oral Pathology, Porto Alegre, Rio Grande do Sul 90035-003, Brazil

^bUniversidade Federal do Rio Grande do Sul, School of Dentistry, Department of Oral Medicine, Porto Alegre, Rio Grande do Sul 90035-003, Brazil

^cUniversity of São Paulo, School of Dentistry, Department of Dentistry, São Paulo, São Paulo 05508-000, Brazil

^dUniversity of Michigan, School of Dentistry, Laboratory of Epithelial Biology, Department of Periodontics and Oral Medicine, Ann Arbor, Michigan 48109-1078

Abstract. Oral lichen planus (OLP) is a relatively common chronic mucocutaneous inflammatory disease and a search for novel therapeutic options has been performed. We sought to compare the efficacy of laser phototherapy (LPT) to topical clobetasol propionate 0.05% for the treatment of atrophic and erosive OLP. Forty-two patients with atrophic/erosive OLP were randomly allocated to two groups: clobetasol group ($n = 21$): application of topical clobetasol propionate gel (0.05%) three times a day; LPT group ($n = 21$): application of laser irradiation using InGaAlP diode laser three times a week. Evaluations were performed once a week during treatment (Days 7, 14, 21, and 30) and in four weeks (Day 60) and eight weeks (Day 90) after treatment. At the end of treatment (Day 30), significant reductions in all variables were found in both groups. The LPT group had a higher percentage of complete lesion resolution. At follow-up periods (Days 60 and 90), the LPT group maintained the clinical pattern seen at Day 30, with no recurrence of the lesions, whereas the clobetasol group exhibited worsening for all variables analyzed. These findings suggest that the LPT proved more effective than topical clobetasol 0.05% for the treatment of OLP. © 2014 Society of Photo-Optical Instrumentation Engineers (SPIE) [DOI: 10.1117/1.JBO.19.6.068002]

Keywords: oral lichen planus; clobetasol propionate 0.05%; laser phototherapy; recurrence; treatment; randomized controlled trial; topical corticosteroid.

Paper 140169R received Mar. 14, 2014; revised manuscript received Apr. 29, 2014; accepted for publication Apr. 30, 2014; published online Jun. 2, 2014.

1 Introduction

Lichen planus is a relatively common chronic mucocutaneous inflammatory condition that affects ~0.3% to 2.3% of adults.¹⁻³ Clinically, oral lichen planus (OLP) is classified into three major types: reticular, atrophic, and erosive.^{4,5} The reticular form is the most common and is typically asymptomatic. In contrast, the atrophic and erosive forms present erythematous, ulcerative areas leading to symptoms ranging from a burning sensation to severe pain.^{4,5} Patients with OLP often experience periods of remission and exacerbation, which may be related to psychological disorders and emotional stress, although divergent opinions are found regarding the psychological component.⁶⁻⁸

Although there is no cure for OLP, a number of treatments with topical or systemic corticosteroids, immunosuppressors, and immunomodulators are able to improve the clinical appearance of the lesions and reduce the degree of pain.⁸⁻¹⁵ Despite the clear potential for controlling OLP, few studies¹⁶⁻²⁰ have used laser phototherapy (LPT) for this purpose. LPT has been widely used in several inflammatory conditions.²¹⁻²⁷ The main effects of this therapy are analgesia, biomodulation, and the acceleration of wound healing.²⁶⁻³⁷ LPT has advantages over current

OLP therapies such as noninvasiveness and the absence of side effects.

The aim of the present study was to compare the efficacy of LPT in comparison to a topical corticosteroid for the management of signs and symptoms of atrophic and erosive OLP. Analyses were performed regarding the resolution of atrophic/erosive lesions, chewing function, swallowing, fluid intake, and altered sense of taste. Moreover, the association of these data with the degree of anxiety in the patients was evaluated.

2 Methods

2.1 Study Design

The present single-center, randomized, controlled, single-blind study received approval from the Human Research Ethics Committee (HCPA protocol 11-0365). All participants signed a statement of informed consent prior to any clinical procedure.

2.2 Participants, Interventions, Randomization, and Blinding

Forty-two consecutive adult patients with OLP were enrolled in the study between February 2012 and November 2012. The sample size was calculated according to previously published

*Address all correspondence to: Manoela Domingues Martins, E-mail: manomartins@gmail.com

articles.¹²⁻¹⁴ Inclusion criteria were age 21 years or older, symptomatic atrophic/erosive OLP, and histopathological diagnosis of OLP based on the criteria proposed by the World Health Organization. The exclusion criteria were pregnant or nursing women, histological signs of dysplasia, OLP therapy in the previous three months, amalgam restoration near the lesions, and the use of medications associated with oral lichenoid reaction. Tabagism was not considered exclusion criteria for this study.

The patients were randomly assigned to one of the two treatment groups using computer-generated random number tables. Only one researcher knew in which group the patients were allocated. This unblinded researcher was not involved in any evaluation during and after the treatments. The patient was not blinded to the treatment.

The clobetasol group consisted of 21 subjects who received topical clobetasol propionate gel (0.05%), and the LPT group consisted of 21 subjects submitted to laser therapy. Figure 1 displays the study flowchart. The participants received verbal and written instructions on how to apply all the medications used.

2.3 Topical Clobetasol Propionate 0.05%

The medication was prepared with a hydroxyethyl cellulose gel and prepackaged (15 g) in a labeled tube by a pharmacist. Only two nonconsecutive missing applications were accepted.

To evaluate possible systemic absorption, blood cortisol levels were monitored at 8:00 am in the second (Day 14) and fourth (Day 30) week of treatment considering a normal range from 5.0 to 25 µg/dl.³⁸

2.4 Laser Phototherapy

LPT was administered by a single professional using a continuous wave diode laser (InGaAlP; MM Optics, São Carlos, São Paulo, Brazil) with a wavelength of 660 nm (visible red). Irradiation was performed in punctual contact mode with a spot size of 0.04 cm², power output of 40 mW, output density of 1000 mW/cm², energy density of 6 J/cm², 6-s exposure time per point, and 0.24 J of total energy per point. The number

of points varied based on lesion size; therefore, it was not possible to calculate the total dose for all the cases. LPT was administered three times a week (Monday, Wednesday, and Friday) for four consecutive weeks, totaling 12 sessions. The output power of the equipment was checked using a power meter (Laser Check; MMOptics LTDA, São Paulo, Brazil).

2.5 Candidiasis Prevention

All patients received prophylactic anti-mycotic medication (Nystatin oral suspension 100,000 USP/ml, Micostatin®; Bristol-Myers Squibb Brasil S.A, São Paulo, Brazil) administered three times daily.^{8,39} The medication was delivered in individual 5-ml dispensers. The patient used an anti-mycotic during all the days of treatment with clobetasol and LPT. During follow-up, the medication was discontinued.

2.6 Clinical Evaluation

All patients were evaluated at baseline (Day 0), once a week during treatment (Days 7, 14, 21, and 30) as well as at four weeks (Day 60) and eight weeks (Day 90) after the discontinuation of treatment (follow-up period) (Fig. 2). Evaluations were performed by a single professional who was blinded to the allocation of the participants to the different treatment groups. Evaluations involved the recording of symptoms, clinical signs, functional scores, Beck anxiety inventory (BAI), and photography. At each evaluation, the patients in both groups were asked to report any unusual effects that might have been related to the therapy protocol.

2.6.1 Clinical scores

The clinical data were scored:⁴⁰ Score 0: no lesions; Score 1: hyperkeratotic lesions; Score 2: atrophic area ≤1 cm²; Score 3: atrophic area >1 cm²; Score 4: erosive area ≤1 cm²; and Score 5: erosive area >1 cm².

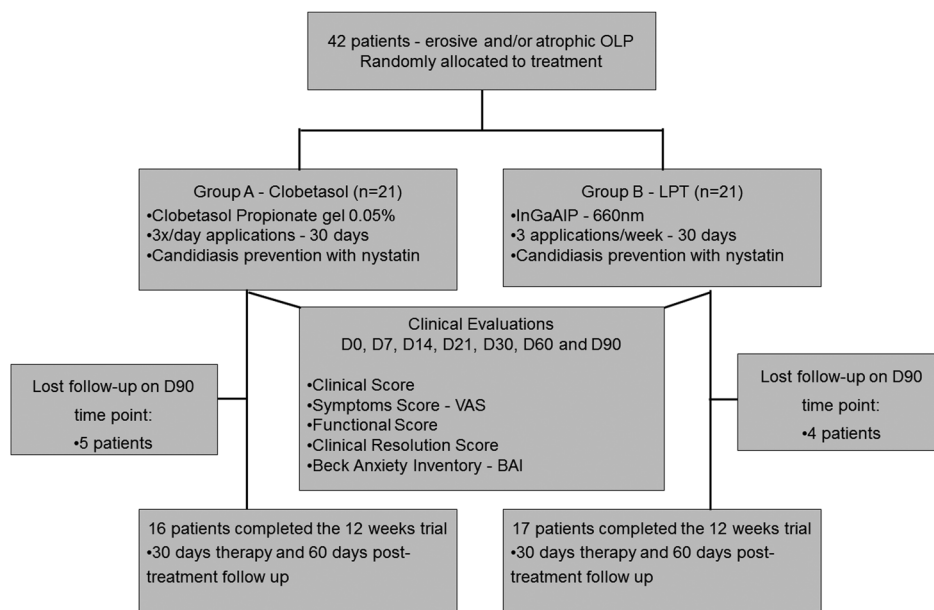


Fig. 1 Flowchart showing subject enrollment and follow-up.

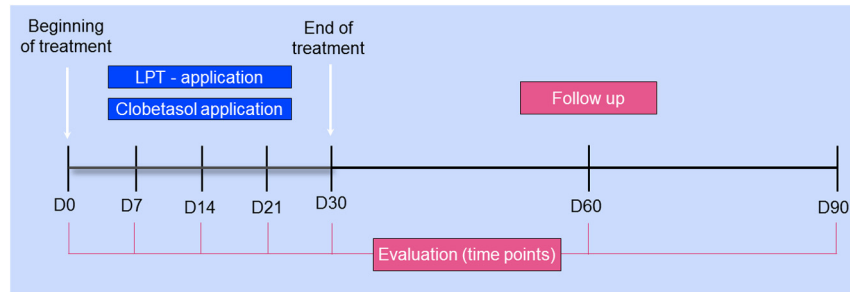


Fig. 2 Diagram of experimental protocol employed.

2.6.2 Symptom scores

Symptom scores were determined using a visual analogue scale (VAS).

2.6.3 Functional scores

Functional scores analyzed the chewing function; swallowing, fluid intake, and altered sense of taste were assessed. The functional scores were recorded as described by Lilleby et al.:⁴¹ no difficulty = 0 points; mild difficulty = 1 point; moderate difficulty = 2 points; severe difficulty = 3 points; and impossible = 4 points.

2.6.4 Clinical resolution (CR) and recurrence rates (RR)

The CR score was evaluated at Day 30 and classified⁴² as: Complete resolution—absence of symptoms and the remission of all atrophic/erosive lesions regardless of any persisting hyperkeratotic lesions. Partial resolution—decrease in but not the complete remission of atrophic/erosive areas and symptoms. No response—maintenance or worsening of the baseline condition.

The RR was analyzed on Days 60 and 90 by comparisons to the patient's condition on Day 30. The absence of recurrence was recorded when the patient maintained the same clinical aspect as that found on Day 30 and recurrence was recorded in the presence of new atrophic and/or erosive lesions at the same site in the follow-up period.

2.6.5 Beck anxiety inventory

The BAI is a questionnaire with 21 multiple-choice items addressing how the patient felt in the previous week regarding common symptoms of anxiety. The score ranges from 0 to 63 and is classified as minimal anxiety (score: 0 to 10), mild anxiety (score: 11 to 20), moderate anxiety (score: 21 to 30), and severe anxiety (score: 31 to 63). The BAI was administered at every evaluation day.

2.7 Statistical Analysis

Statistical analysis was carried out using the SPSS version 18.0 (SPSS Inc., Chicago, Illinois). Data were analyzed using a generalized estimating equations (GEE) test, which combined tests for treatment differences and changes in treatment response over time. The GEE followed by Bonferroni's posthoc test was used to determine the significance of differences between therapies over time considering the VAS score, CS, functional scores, and CR score. The chi-squared test was used to analyze the RR. All statistical tests were performed with a significance

level of 5% ($p < 0.05$). The statistical tests used took into account the correlated nature of the repeated measures of each patient. Analyses were performed on an intention-to-treat basis.

3 Results

Table 1 summarizes the characteristics of the patients. All patients completed the treatment period and underwent the evaluation on Day 60. Nine patients (five in the clobetasol group and four in the LPT group) did not undergo the evaluation on Day 90 (Fig. 1).

3.1 Clinical Scores

The CS results are graphically represented in Fig. 3. At baseline (Day 0), the patients exhibited lesions with atrophic and erosive areas associated or not to hyperkeratotic lesions, with a similar mean CS in both groups. The CS remained similar in both groups, decreasing progressively through to Day 21. However, from Day 30 to the end of the follow-up period (Day 90), the LPT group had significantly lower scores in comparison to the clobetasol group ($p < 0.001$). At Day 90, the LPT group exhibited more hyperkeratotic lesions and fewer atrophic/erosive lesions than the clobetasol group ($p < 0.001$). Moreover, the clobetasol group demonstrated a worsening of clinical aspects, with the recurrence of atrophic and erosive lesions. Figure 4 illustrates the CS findings in a patient from the LPT group.

3.2 Symptom Score

All patients had symptoms at baseline (Day 0). The overall mean VAS score was $6.6 (\pm 2.0)$, with no statistically significant difference between groups. The mean VAS scores decreased significantly in both groups by Day 14 ($p < 0.001$) (Fig. 5). The change in mean VAS scores did not differ significantly between groups during treatment. In the follow-up period, the LPT group maintained a stable mean VAS, whereas a significant increase was found in the clobetasol group, leading to significant differences groups ($p < 0.05$).

3.3 Functional Scores

On Day 0, both groups exhibited moderate difficulty in chewing and fluid intake as well as an altered sense of taste. Both groups demonstrated significant improvements in the four aspects analyzed throughout treatment ($p < 0.001$). At Day 30, improvements were found in both groups in all functional scores. In the follow-up period, a significant difference between groups

Table 1 General characteristics of sample at baseline (demographic variables, symptoms, affected sites, and clinical aspects).

Baseline characteristic	Clobetasol group (n = 21)	LPT (n = 21)	Total (n = 42)	p-value*
Gender, n (%)				
Male	3(14.3%)	4(19%)	7(16.7%)	NS
Female	18(85.7%)	17(81%)	35 (83.3%)	NS
Age, year, mean SD	61.33 (±11.85)	55.14 (±15.96)	58.2 (±14.23)	NS
Mean duration, months	48.48 (±39.64)	44.81 (±51.05)	46.6 (±44.6)	NS
VAS, mean SD	6.52 (±1.74)	6.74 (±2.27)	6.63 (±2.0)	NS
Site of involvement				
Tongue	54 (53.5%)	47 (46.5%)	101 (45.1%)	NS
Buccal mucosa	33 (47.8%)	36 (52.2%)	69 (30.8%)	NS
Lips / Labial mucosa	13(36.1%)	23 (63.9%)	36(16.1%)	0.01
Floor of mouth	1 (14.3%)	6 (85.7%)	7(3.1%)	NS
Gingiva	4 (66.7%)	2(33.3%)	6(2.7%)	NS
Palate	1 (33.3%)	2 (66.7%)	3(1.3%)	NS
Alveolar ridge	0	2(100%)	2 (0.9%)	NS
Clinical aspects of lesions				
Reticular	11 (10.4%)	23(19.5%)	44(18.8%)	0.06
Erosive	53 (50.0%)	72 (61.0%)	125 (53.4%)	0.06
Atrophic	42 (39.6%)	23(19.5%)	65 (27.8%)	0.04

was found only with regard to altered sense of taste, for which the clobetasol group had a worse behavior (Fig. 6).

3.4 Clinical Resolution and Recurrence Rates

Partial or complete CR was achieved in both groups. Complete resolution at Day 30 occurred in 28.6% (6 patients) of the clobetasol group and 61.9% (13 patients) of the LPT group.

Table 2 displays the RR in both groups. At Day 60, only one case of recurrence (4.8%) was found in the LPT group, whereas

10 cases (47.6%) were found in the clobetasol group ($p < 0.001$). At Day 90, the LPT group had a higher percentage of patients with no signs of recurrence, but the difference between groups did not achieve statistical significance ($p = 0.276$).

3.5 Beck Anxiety Inventory

The overall mean BAI score at baseline (Day 0) was 34.02 ± 9.46 (32.9 in the clobetasol group and 35.1 in the

Group	Baseline		Treatment			Follow up		p-value*
	D0	D7	D14	D21	D30	D60	D90	
Clobetasol	3.52 ^{aA} (±0.12)	2.52 ^{aA} (±0.13)	1.98 ^{aA} (±0.08)	1.76 ^{aA} (±0.09)	1.54 ^{aA} (±0.12)	2.06 ^{aA} (±0.15)	2.23 ^{aA} (±0.26)	< 0.001
LPT	3.57 ^{aA} (±0.17)	2.70 ^{aA} (±0.14)	2.06 ^{aA} (±0.12)	1.73 ^{aA} (±0.08)	0.98 ^{aB} (±0.07)	1.16 ^{aB} (±0.15)	1.09 ^{aB} (±0.11)	< 0.001
p-value (comparison between groups) **	0.822	0.345	0.601	0.790	0.0006	0.0003	0.0005	

Different lowercase letters on lines (intra-group analysis) denote significant difference ($p < 0.05$, GEE test); Different uppercase letters in columns (inter-group analysis) denote significant difference ($p < 0.05$, GEE test). * significant difference inter-group analysis

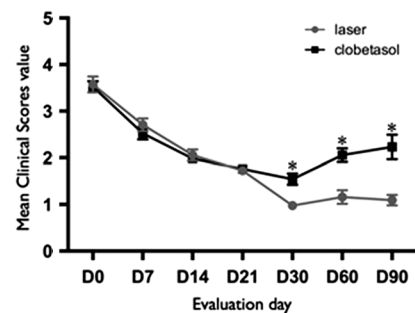


Fig. 3 Mean clinical scores (standard error of mean) in clobetasol and laser phototherapy (LPT) groups during experimental period; Clobetasol group presented significant (*) worsening of clinical aspects, with more atrophic and erosive lesions than LPT group at Days 30, 60, and 90 (A and B).

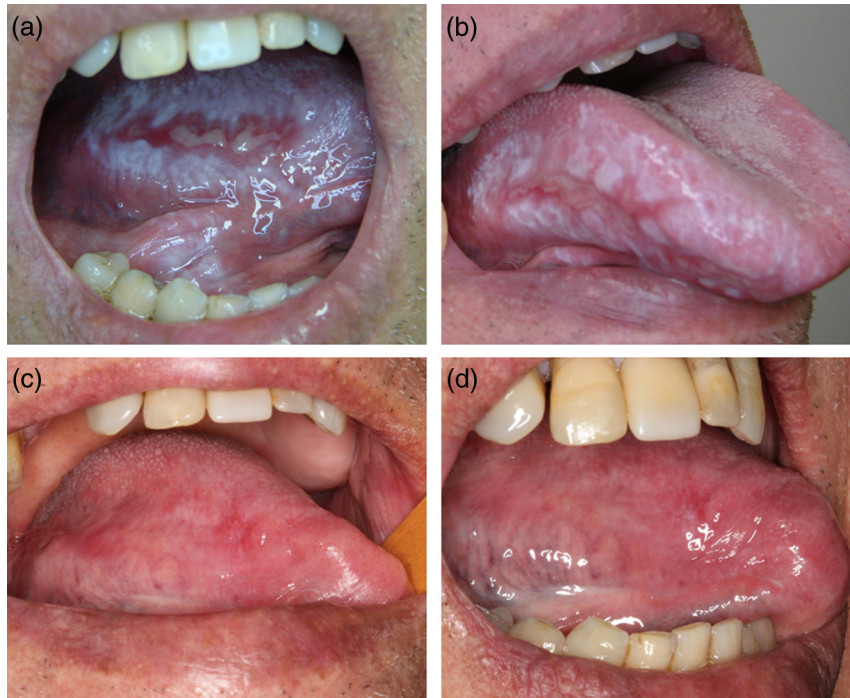


Fig. 4 Effect of LPT on lateral border of tongue in 82-year-old male; (a) erosive/ulcerative lesion at Day 0; (b) erosive lesion at Day 7; (c) effect of LPT at Day 30; (d) clinical aspect of tongue at Day 90.

Group	Baseline		Treatment			Follow up		p-value*
	D0	D7	D14	D21	D30	D60	D90	
Clobetasol	6.52 ^a A (±0.38)	3.26 ^b A (±0.50)	2.50 ^c A (±0.44)	2.29 ^c A (±0.43)	1.67 ^c A (±0.38)	2.86 ^c A (±0.56)	2.81 ^c A (±0.62)	< 0.001
LPT	6.74 ^a A (±0.50)	4.17 ^b A (±0.52)	2.79 ^c A (±0.53)	2.45 ^c A (±0.44)	1.05 ^c A (±0.29)	1.21 ^d B (±0.31)	0.79 ^d B (±0.27)	< 0.001
p-value (comparison between groups) **	0.733	0.216	0.680	0.789	0.202	0.015	0.005	

Different lowercase letters on lines (intra-group analysis) denote significant difference ($p < 0.05$, GEE test); Different uppercase letters in columns (inter-group analysis) denote significant difference ($p < 0.05$, GEE test). * significant difference inter-group analysis

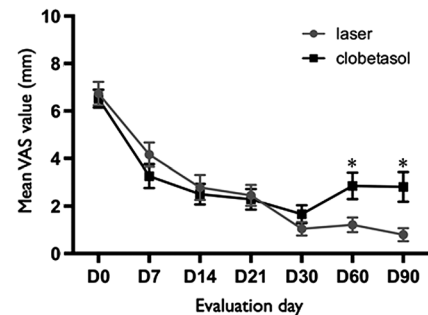


Fig. 5 Mean symptom (visual analogue scale) scores (standard error of mean) in clobetasol and LPT groups during experimental period; Both groups demonstrated reductions in pain throughout treatment. Clobetasol group exhibited significant (*) increase in pain on Days 60 and 90.

LPT group), demonstrating severe anxiety. Similar significant decreases were found in both groups throughout treatment ($p < 0.001$). At Day 90, the clobetasol group demonstrated an increase in anxiety, whereas the LPT group maintained a constant mean score, with a significant difference between groups ($p < 0.05$) (Fig. 7).

3.6 Side Effects

Three patients (14.3%) of the clobetasol group reported a transient local burning sensation immediately after the first two days of drug application and two (9.5%) reported gastrointestinal distress, which was resolved with the concomitant intake of omeprazole. The mean cortisol level in the clobetasol group was 8.85 ± 3.59 on Day 14 and 10.67 ± 3.96 on Day 30, which were within the normal endogenous cortisol pattern (5.0 to $25 \mu\text{g/dl}$).³⁸ No side effects were reported in the LPT group.

4 Discussion

Among the therapeutic options available to OLP, corticosteroids are the most widely accepted, but a definitive cure has not yet been achieved.^{8-11,42-44} A search for alternative methods that are capable of modulating the inflammatory response related to the disease seems reasonable.⁴⁰ LPT is a promising modality that has been employed in different adverse health conditions.²¹⁻²⁷ Few studies have employed LPT as a treatment for OLP.¹⁶⁻²⁰ The present investigation compared the efficacy of clobetasol and LPT in the treatment of atrophic and erosive OLP. Overall, both topical clobetasol 0.05%, and LPT were effective in the management of OLP, with reductions in clinical, symptom, functional and BAI scores throughout the treatment period. These results were considered a successful outcome based on the conversion of symptomatic erosive lesions into reticular lesions with barely any symptoms.^{1,45}

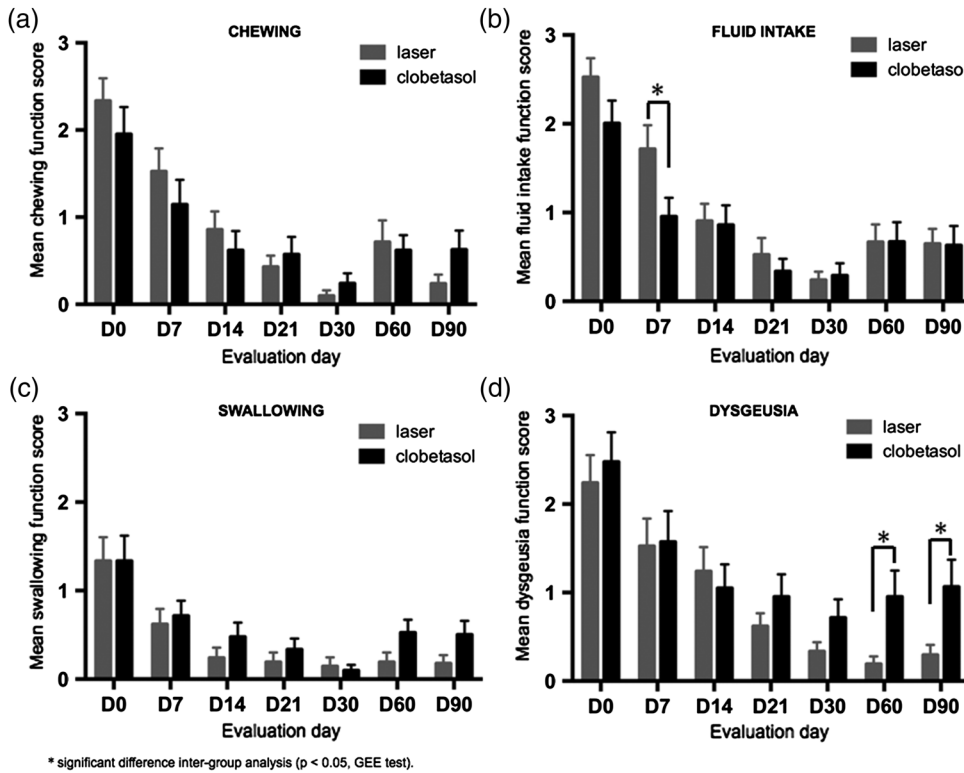


Fig. 6 Mean functional scores (standard error of mean) in clobetasol and LPT groups during experimental period; Both groups demonstrated significant improvements in chewing (a), fluid intake (b), swallowing (c) and altered sense of taste (d) throughout treatment, with significant (*) difference between groups in fluid intake at Day 7 (B). Significant (*) worsening in sense of taste in clobetasol group during follow-up period (Days 60 and 90).

The recurrence of OLP lesions after the end of treatment with clobetasol has been described as a rebound effect that can occur when the corticosteroid is abruptly discontinued,¹⁴ as found in the present study. Moreover, the literature describes that systemic administration of corticosteroid led to improvements in all variables analyzed of OLP, despite the inferior performance of clobetasol in comparison to LPT especially during follow-up periods. These findings are in agreement with data described in the previous studies, which report rates of improvements in clinical signs and symptoms ranging from 56% to 100% associated to corticosteroid^{13,46-48} local side effects with the use of this medication. In the present study, clobetasol was well

Table 2 Recurrence rate in clobetasol and LPT groups at follow up (Days 60 and 90); significant worsening in CS in clobetasol group at Day 60.

		Recurrence(%)	No recurrence(%)	Total
D60	Clobetasol	10(47.6)	11 (52.4)	21
	LPT	1 (4.8)	20 (95.2)	21
	Total	11 (26.2)	31 (73.8)	42
D90	Clobetasol	6 (37.5)	10(62.5)	16
	LPT	3(17.6)	14(82.4)	17
	Total	9 (27.3)	24 (72.7)	33

tolerated and caused no change in endogenous cortisol levels. However, local adverse effects were reported, such as a burning sensation and gastrointestinal discomfort, which is in agreement with data described in the previous studies.^{13,48} These effects were mild and transient and did not force patients to abandon the study, which demonstrates that topical clobetasol treatment for 30 days is a safe treatment modality with few side effects.

The LPT positive effects on erosive and ulcerative OLP lesions could be explained by its biological activity in a diversity of cell types, such as fibroblasts^{36,37} and epithelial cells,^{34,49} which are key participants in the mucosal healing process. LPT activates signaling pathways that lead to cell proliferation and migration,^{34,35} controls oxidative stress,²⁸ modulates the production of several cytokines,^{31-33,50} and regulates several genes that are closely involved in the wound healing process.³⁴ However, it is difficult to compare the results of the present study with data from the literature, as few studies have analyzed the effect of LPT on OLP¹⁶⁻²⁰ and only one randomized clinical trial compared LPT with standard therapy (dexamethasone).¹⁸ The previous studies also found significant pain and clinical improvements in OLP with the use of LPT.¹⁶⁻²⁰ In the present investigation, the most striking finding was the maintenance of the improvement in clinical signs and symptoms up to two months after the end of treatment with LPT, demonstrating longer control of OLP in comparison to that achieved with clobetasol.

In the present study, the patients in both groups exhibited significant improvements in psychological factors. This finding can be attributed to the reduction in symptoms, improvement in oral functions, and the attention that patients received during the

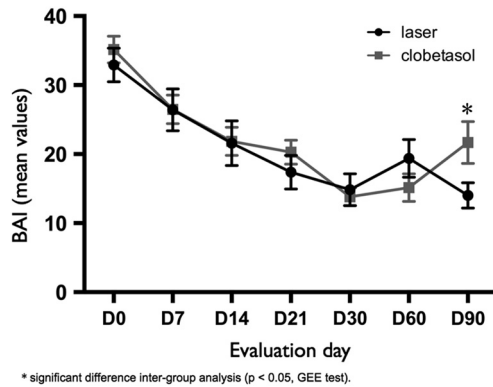


Fig. 7 Mean Beck anxiety inventory (BAI) scores (standard error of mean) in clobetasol and LPT groups during experimental period.

four weeks of treatment. Although few studies have investigated the association between the BAI score and OLP, this questionnaire is a helpful tool for analyzing the clinical course of psychological aspects in patients with this condition.^{6,7,51,52} Considering the interplay between one's emotional state and the course of OLP,⁶ psychological support should be considered as a complementary strategy in the management of OLP, particularly in patients who do not respond well to treatment.

The suggestion that OLP can undergo malignant transformation into oral squamous cell carcinoma has been debated for decades. Some authors have reported that the use of clinical and histopathological criteria are sufficient for an accurate diagnosis and that cases associated to OLP transformation are generally related to a failure to fulfill these criteria.^{53–56} Premalignant oral epithelium is typically defined by histopathologic criteria as different grades of epithelial dysplasia depending on the severity of the microscopic changes. According to Van der Meij et al.,⁵⁶ only oral lichenoid lesions are endowed with malignant transformation, but not OLP. All patients included in this study were biopsied and only cases without dysplasia that fulfill all criteria for OLP were selected.

The safety in using LPT in the oral mucosa is always a concern. We have recently shown that the low doses of irradiation do not induce genomic instability as judged by two distinct markers for genomic integrity.⁵⁷ Indeed, a lack in the accumulation of DNA double strand breaks or absence of the BRCA1 DNA damage repair molecule suggests that the low energy densities of LPT can serve as a safe therapeutic strategy for lesions and ulcers from the oral mucosa.⁵⁷

To the best of our knowledge, this is the first clinical trial to evaluate the effects of LPT in comparison with topical clobetasol 0.05% for the treatment of OLP involving the analysis of clinical behavior, symptoms, oral function, and psychological aspects. The results indicate that the LPT is more effective than clobetasol for treating OLP lesions and preventing their recurrence. The data also strongly indicate that the LPT is a promising therapeutic strategy for OLP. The only disadvantage in the use of LPT is the upfront equipment costs and required specialized training that surpasses the costs of using clobetasol. Further studies are currently underway to investigate the mechanisms underlying the effects of LPT on OLP as well as the mechanisms involved in the pathobiology of this condition.

Acknowledgments

This study was funded by the Postgraduate Research Group of the Porto Alegre University Hospital (GPPG/FIPE: process

number 11-0365), the Coordenação de Aperfeiçoamento de Pessoal de Nível Superior (CAPES) and the Universidade Federal do Rio Grande do Sul (UFRGS). The funders had no role in the study design, data collection, data analysis, decision to publish or preparation of the manuscript. There was no industrial funding for the study.

References

1. P. Parashar, "Oral lichen planus," *Otolaryngol. Clin. North Am.* **44**(1), 89–107 (2011).
2. J. L. Xue et al., "A clinical study of 674 patients with oral lichen planus in China," *J. Oral Pathol. Med.* **34**(8), 467–472 (2005).
3. M. R. Payeras et al., "Oral lichen planus: focus on etiopathogenesis," *Arch. Oral Biol.* **58**(9), 1057–1069 (2013).
4. D. Eisen, "The clinical manifestations and treatment of oral lichen planus," *Dermatol. Clin.* **21**(1), 79–89 (2003).
5. C. Scully and M. Carrozzo, "Oral mucosal disease: Lichen planus," *Br. J. Oral Maxillofac. Surg.* **46**(1), 15–21 (2008).
6. J. L. Rojo-Moreno et al., "Psychologic factors and oral lichen planus. A psychometric evaluation of 100 cases," *Oral Surg. Oral Med. Oral Pathol. Oral Radiol. Endod.* **86**(6), 687–691 (1998).
7. C. M. Allen et al., "Relation of stress and anxiety to oral lichen planus," *Oral Surg. Oral Med. Oral Pathol.* **61**(1), 44–46 (1986).
8. K. Thongprasom and K. Dhanuthai, "Steroids in the treatment of lichen planus: a review," *J. Oral Sci.* **50**(4), 377–385 (2008).
9. G. Lodi et al., "Interventions for treating oral lichen planus: a systematic review," *Br. J. Dermatol.* **166**(5), 938–947 (2012).
10. S. Cheng et al., "Interventions for erosive lichen planus affecting mucosal sites," *Cochrane Database Syst. Rev.* **2**, CD008092 (2012).
11. V. Crincoli et al., "Oral lichen planus: update on etiopathogenesis, diagnosis and treatment," *Immunopharmacol. Immunotoxicol.* **33**(1), 11–20 (2011).
12. G. Campisi et al., "A new delivery system of clobetasol-17-propionate (lipid-loaded microspheres 0.025%) compared with a conventional formulation (lipophilic ointment in a hydrophilic phase 0.025%) in topical treatment of atrophic/erosive oral lichen planus. A Phase IV, randomized, observer-blinded, parallel group clinical trial," *Br. J. Dermatol.* **150**(5), 984–990 (2004).
13. D. Conrotto et al., "Ciclosporin vs. clobetasol in the topical management of atrophic and erosive oral lichen planus: a double-blind, randomized controlled trial," *Br. J. Dermatol.* **154**(1), 139–145 (2006).
14. G. Corrocher et al., "Comparative effect of tacrolimus 0.1% ointment and clobetasol 0.05% ointment in patients with oral lichen planus," *J. Clin. Periodontol.* **35**(3), 244–249 (2008).
15. R. Laejjendecker et al., "A comparison of treatment of oral lichen planus with topical tacrolimus and triamcinolone acetonide ointment," *Acta. Derm. Venereol.* **86**(3), 227–229 (2006).
16. A. Cafaro et al., "Clinical evaluation of the efficiency of low-level laser therapy for oral lichen planus: a prospective case series," *Lasers Med. Sci.* **29**(1), 185–190 (2014).
17. F. Agha-Hosseini, E. Moslemi, and I. Mirzaei-Dizgah, "Comparative evaluation of low-level laser and CO(2) laser in treatment of patients with oral lichen planus," *Int. J. Oral Maxillofac. Surg.* **41**(10), 1265–1269 (2012).
18. H. H. Hajarm, F. Falaki, and O. Mahdavi, "A comparative pilot study of low intensity laser versus topical corticosteroids in the treatment of erosive-atrophic oral lichen planus," *Photomed. Laser Surg.* **29**(6), 421–425 (2011).
19. A. Cafaro et al., "Effect of low-level laser irradiation on unresponsive oral lichen planus: early preliminary results in 13 patients," *Photomed. Laser Surg.* **28**(Suppl 2), S99–S103 (2010).
20. N. Misra et al., "Efficacy of diode laser in the management of oral lichen planus," *BMJ Case Rep.* pii, bcr2012007609 (2013).
21. P. V. Peplow, T. Y. Chung, and G. D. Baxter, "Laser photobiomodulation of wound healing: a review of experimental studies in mouse and rat animal models," *Photomed. Laser Surg.* **28**(3), 291–325 (2010).
22. J. T. Hopkins et al., "Low-level laser therapy facilitates superficial wound healing in humans: a triple-blind, sham-controlled study," *J. Athl. Train.* **39**(3), 223–229 (2004).

23. C. Migliorati et al., "Systematic review of laser and other light therapy for the management of oral mucositis in cancer patients," *Support Care Cancer* **21**(1), 333–341 (2013).
24. T. O. De Souza et al., "Clinical evaluation of low-level laser treatment for recurring aphthous stomatitis," *Photomed. Laser Surg.* **28**(Suppl 2), S85–S88 (2010).
25. C. P. Eduardo et al., "Prevention of recurrent herpes labialis outbreaks through low-intensity laser therapy: a clinical protocol with 3-year follow-up," *Lasers Med. Sci.* **27**(5), 1077–1083 (2012).
26. R. Forney and T. Mauro, "Using lasers in diabetic wound healing," *Diabetes Technol. Ther.* **1**(2), 189–192 (1999).
27. M. A. Martins et al., "Association of laser phototherapy with PRP improves healing of bisphosphonate-related osteonecrosis of the jaws in cancer patients: a preliminary study," *Oral Oncol.* **48**(1), 79–84 (2012).
28. X. Gao and D. Xing, "Molecular mechanisms of cell proliferation induced by low power laser irradiation," *J. Biomed. Sci.* **16**(1), 1–16 (2009).
29. D. H. Hawkins and H. Abrahamse, "Time-dependent responses of wounded human skin fibroblasts following phototherapy," *J. Photochem. Photobiol. B.* **88**(2–3), 147–155 (2007).
30. J. M. Bjordal et al., "Low-level laser therapy in acute pain: a systematic review of possible mechanisms of action and clinical effects in randomized placebo-controlled trials," *Photomed. Laser Surg.* **24**(2), 158–168 (2006).
31. Y. Sakurai, M. Yamaguchi, and Y. Abiko, "Inhibitory effect of low-level laser irradiation on LPS-stimulated prostaglandin E2 production and cyclooxygenase-2 in human gingival fibroblasts," *Eur. J. Oral Sci.* **108**(1), 29–34 (2000).
32. M. S. Moreira et al., "Effect of laser phototherapy on wound healing following cerebral ischemia by cryogenic injury," *J. Photochem. Photobiol. B.* **105**(3), 207–215 (2011).
33. M. S. Moreira et al., "Effect of phototherapy with low intensity laser on local and systemic immunomodulation following focal brain damage in rat," *J. Photochem. Photobiol. B.* **97**(3), 145–151 (2009).
34. A. C. A. Pelliccioli et al., "Laser phototherapy accelerates oral keratinocyte migration through the modulation of the PI3K signaling pathway," *J. Biomed. Opt.* **19**(2), 028002 (2014).
35. V. P. Wagner et al., "Influence of different energy densities of laser phototherapy on oral wound healing," *J. Biomed. Opt.* **18**(12), 128002 (2013).
36. L. Almeida-Lopes et al., "Comparison of the low level laser therapy effects on cultured human gingival fibroblasts proliferation using different irradiance and same fluence," *Lasers Surg. Med.* **29**(2), 179–184 (2001).
37. M. M. Marques et al., "Effect of low-power laser irradiation on protein synthesis and ultrastructure of human gingival fibroblasts," *Lasers Surg. Med.* **34**(3), 260–265 (2004).
38. P. Rotman-Pikielny et al., "Serum cortisol levels in patients admitted to the department of medicine: prognostic correlations and effects of age, infection, and comorbidity," *Am. J. Med. Sci.* **332**(2), 61–67 (2006).
39. M. Carbone et al., "Systemic corticosteroid therapy of oral vesiculorecursive diseases (OVED). An open trial," *Minerva Stomatol.* **47**(10), 479–487 (1998).
40. K. Thongprasom et al., "Relative efficacy of fluocinolone acetonide compared with triamcinolone acetonide in treatment of oral lichen planus," *J. Oral Pathol. Med.* **21**(10), 456–458 (1992).
41. K. Lilleby et al., "A prospective, randomized study of cryotherapy during administration of high-dose melphalan to decrease the severity and duration of oral mucositis in patients with multiple myeloma undergoing autologous peripheral blood stem cell transplantation," *Bone Marrow Transplant.* **37**(11), 1031–1035 (2006).
42. M. Carrozzo et al., "Oral lichen planus in patients infected or noninfected with hepatitis C virus: the role of autoimmunity," *J. Oral Pathol. Med.* **28**(1), 16–19 (1999).
43. C. Scully et al., "Update on oral lichen planus: etiopathogenesis and management," *Crit. Rev. Oral Biol. Med.* **9**(1), 86–122 (1998).
44. K. Thongprasom, C. Prapinjumrun, and M. Carrozzo, "Novel therapies for oral lichen planus," *J. Oral Pathol. Med.* **42**(10), 721–727 (2013).
45. J. J. Thorn et al., "Course of various clinical forms of oral lichen planus. A prospective follow-up study of 611 patients," *J. Oral Pathol.* **17**(5), 213–218 (1988).
46. M. Carbone et al., "Course of oral lichen planus: a retrospective study of 808 northern Italian patients," *Oral Dis.* **15**(3), 235–243 (2009).
47. L. Lo Muzio et al., "The treatment of oral aphthous ulceration or erosive lichen planus with topical clobetasol propionate in three preparations: a clinical and pilot study on 54 patients," *J. Oral Pathol. Med.* **30**(10), 611–617 (2001).
48. S. Sonthalia and A. Singal, "Comparative efficacy of tacrolimus 0.1% ointment and clobetasol propionate 0.05% ointment in oral lichen planus: a randomized double-blind trial," *Int. J. Dermatol.* **51**(11), 1371–1378 (2012).
49. F. G. Basso et al., "Biostimulatory effect of low-level laser therapy on keratinocytes in vitro," *Lasers Med. Sci.* **28**(2), 367–374 (2013).
50. K. P. Fernandes et al., "Effect of photobiomodulation on expression of IL-1beta in skeletal muscle following acute injury," *Lasers Med. Sci.* **28**(3), 1043–1046 (2013).
51. M. Onder et al., "Stress and skin diseases in musicians: evaluation of the Beck depression scale, general psychologic profile (the brief symptom inventory [BSI]), Beck anxiety scale and stressful life events in musicians," *Biomed. Pharmacother.* **54**(5), 258–262 (2000).
52. C. Girardi et al., "Salivary cortisol and dehydroepiandrosterone (DHEA) levels, psychological factors in patients with oral lichen planus," *Arch. Oral Biol.* **56**(9), 864–868 (2011).
53. J. B. Epstein et al., "Oral lichen planus: progress in understanding malignant potential and implications for clinical management," *Oral Surg. Oral Med. Oral Pathol. Oral Radiol. Endod.* **96**(1), 32–37 (2003).
54. M. Gorsky and J. B. Epstein, "Oral lichen planus: malignant transformation and human papilloma virus: a review of potential clinical implications," *Oral Surg. Oral Med. Oral Pathol. Oral Radiol. Endod.* **111**(4), 461–464 (2011).
55. E. H. van der Meij, K. P. Schepman, and I. van der Waal, "The possible premalignant character of oral lichen planus and oral lichenoid lesions: a prospective study," *Oral Surg. Oral Med. Oral Pathol. Oral Radiol. Endod.* **96**(2), 164–171 (2003).
56. E. H. van der Meij, H. Mast, and I. van der Waal, "The possible premalignant character of oral lichen planus and oral lichenoid lesions: a prospective five-year follow-up study of 192 patients," *Oral Oncol.* **43**(8), 742–748 (2007).
57. C. S. Dillenburg et al., "Laser phototherapy triggers production of reactive oxygen species in oral epithelial cells without inducing damage," *J. Biomed. Opt.* **19**(4), 048002 (2014).

Caroline Siviero Dillenburg received her DDS from the Pontifical Catholic University of Rio Grande do Sul, Brazil. She is a master's degree student at the Department of Oral Pathology, School of Dentistry, Federal University of Rio Grande do Sul, Brazil. Her personal research interest is focused on the clinical effects of laser phototherapy in wound repair.

Marco Antonio Trevizani Martins received his DDS from Paulista University, Brazil, and his PhD degree from the University of Sao Paulo, Brazil. He is a full professor at the Department of Oral Pathology, School of Dentistry, Federal University of Rio Grande do Sul, Brazil and Department of Oral Medicine, Hospital de Clínicas de Porto Alegre, Brazil. His personal research interest is focused on the diagnosis and treatment of oral diseases.

Maria Cristina Munerato received her DDS and PhD degrees from the Pontifical Catholic University of Rio Grande do Sul, Brazil. She is a full professor at the Department of Oral Pathology, School of Dentistry, Federal University of Rio Grande do Sul, Brazil and Department of Oral Medicine, Hospital de Clínicas de Porto Alegre, Brazil. Her personal research interest is focused on the diagnosis and treatment of oral diseases.

Marcia Martins Marques DDS, PhD, is a full professor of the Department of Restorative Dentistry, School of Dentistry, University of São Paulo in Brazil. Invited lecturer of the Master of Science in Lasers in Dentistry of the RWTH Aachen University. Her personal research interests are the basic aspects of laser phototherapy in tissue regeneration.

Vinicius Coelho Carrard received his DDS and PhD degrees from the Federal University of Rio Grande do Sul, Brazil. He is a full professor at the Department of Oral Pathology, School of Dentistry,

Federal University of Rio Grande do Sul, Brazil. His personal research interest is the development of alternatives approaches for oral lesions.

Manoel Sant'Ana Filho received his DDS from the Federal University of Rio Grande do Sul, Brazil, and PhD degrees from Pontifical Catholic University of Rio Grande do Sul, Brazil. He is full professor at the Department of Oral Pathology, School of Dentistry, Federal University of Rio Grande do Sul, Brazil. His personal research interest is oral cancer and diagnosis and treatment of oral diseases.

Rogério Moraes Castilho received his DDS from Pontifical Catholic University of Campinas, Brazil, and his PhD degree from the University of Sao Paulo, Brazil. He is an assistant professor at the

Department of Periodontics and Oral Medicine from the University of Michigan, School of Dentistry, and the principal investigator of the Laboratory of Epithelial Biology. His interest is in the molecular mechanism responsible for epigenetically regulating histone modifications and influencing the behavior of epithelial cells.

Manoela Domingues Martins received her DDS from the Federal University of Rio Grande do Sul, Brazil, and PhD degrees from the University of Sao Paulo, Brazil. She is a full professor at the Department of Oral Pathology, School of Dentistry, Federal University of Rio Grande do Sul, Brazil. Her personal research interest is the clinical and basic aspects of laser phototherapy in oral lesions and tissue regeneration.