

# A Virtual Imaging Trial Framework to Study Cardiac CT Blooming Artifacts

Ying Fan, Jed Pack, and Bruno De Man

**Abstract**— Cardiac CT is a safe, accurate, non-invasive method widely employed for diagnosis of coronary artery disease (CAD) and planning therapeutic interventions. Even with state-of-the-art CT technology, calcium blooming artifacts may limit the accuracy of coronary stenosis assessment. A variety of solutions to reduce blooming artifacts have been proposed, including hardware improvements, protocol optimizations, and software deblooming techniques [1-6]. Hardware developments and clinical studies (for protocol optimization or training data generation) can be expensive, time-consuming, and impractical. Hence, there is an opportunity for a Virtual Clinical Trial (VCT) framework [7-8] to help researchers to evaluate the impact of various solutions on calcium blooming and to create training datasets for developing deep learning solutions for deblooming.

In this paper, we present a new VCT framework for generating cardiac CT images with calcium blooming with a variety of CT hardware parameters, CT scan protocols and CT reconstruction kernels. As an example, we use the VCT framework to investigate the impact of three common scan and reconstruction parameters (X-ray tube voltage, focal spot size, and reconstruction kernel) on calcium blooming artifacts. We conclude that tube voltage and reconstruction kernel have the most direct impact on calcium blooming, which is consistent with earlier clinical reports [9-12].

**Index Terms**—Computed tomography, Cardiac CT, Calcium blooming

## I. INTRODUCTION

Cardiac CT Angiography (CCTA) is used for the identification of significant coronary stenoses in patients and is guideline-recommended as a valuable noninvasive alternative in the diagnostic evaluation of CAD [13-14]. One of the main limitations of CCTA is inaccuracy in evaluating calcified lesions. The presence of calcified lesions leads to blooming artifacts in CT images. This may obscure the lumen and cause a false-positive CCTA. Diffuse or extensive calcifications often lead to overestimation or paradoxically, underestimation of coronary stenosis severity.

A variety of solutions to reduce blooming artifacts have been proposed. Hardware improvements have focused on smaller detector cell size to improve spatial resolution [1]. Protocol optimizations have been proposed, either optimizing the X-ray tube voltage to minimize blooming artifacts or subtracting two scans, one with and one without contrast agent [2-3]. Multiple processing techniques have been proposed, including analytical and more recently data-driven deblooming techniques [4-6].

The goal of the research presented in this paper is two-fold. First, we aim to develop a virtual clinical trial (VCT) (or more specifically virtual imaging trial) framework [7-8] to enable inexpensive and relatively fast evaluation of various solutions for calcium blooming. Second, we want to use the VCT framework to evaluate the effect of three example scan/reconstruction parameters: X-ray tube voltage, focal spot size, and reconstruction kernel. In future work, we will use the VCT framework to train and test DL-based deblooming methods.

---

Ying Fan (fan@research.ge.com), Jed D. Pack, and Bruno De Man are with GE Research, Niskayuna, NY.

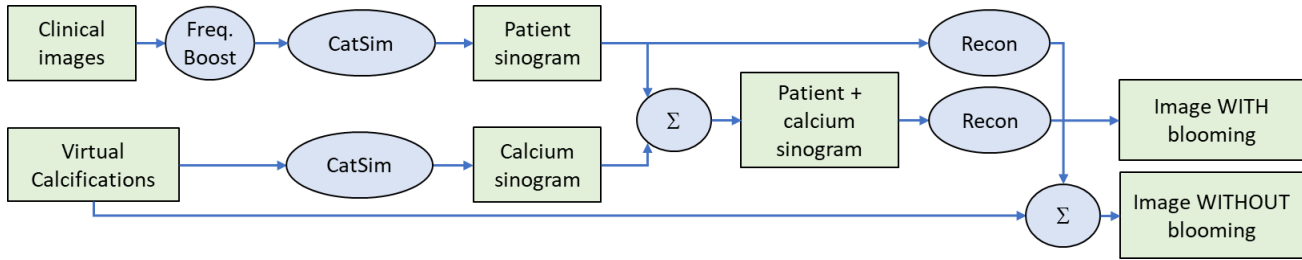


Figure 1. The VCT framework produces images with and without blooming artifacts from patient images and virtual calcifications.

## II. METHODS

Figure 1 shows an overview of the VCT framework. The framework uses two types of data: clinical images and virtual calcifications, which are combined to produce images with and without blooming artifacts, including the following steps.

**Clinical images** - When using existing clinical images as software phantom in CT simulations and reconstructions, some blur is introduced in the process, and the simulated-reconstructed image does not look identical to the original clinical image. To minimize that discrepancy, we developed and optimized a frequency-based blur compensation algorithm to minimize the pixelwise error before and after CT simulation and reconstruction. Figure 2 shows the error image without (left) and with (right) frequency-based blur compensation. The latter shows a very small error indicating that the resulting images are representative for real clinical images in terms of noise and resolution.




Figure 2. Difference between real clinical images and virtual clinical images without (left) and with (right) blur compensation.

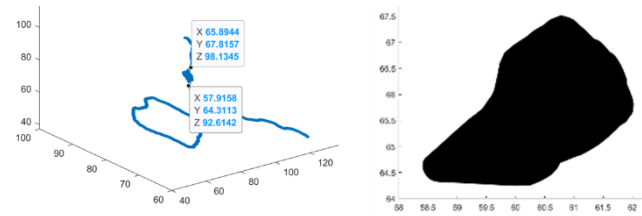


Figure 3. A virtual calcification in the context of a centerline of a coronary artery (left) and a magnified view of the virtual calcification (right).

**Virtual calcifications**– We used an in-house semiautomatic image segmentation tool to develop a three-dimensional mesh models of virtual calcifications, matching the geometry of the surrounding *calcification-free* coronary arteries (Figure 3). The three-dimensional mesh representation is converted to a voxelized representation with a resolution of 0.1 mm, so it can conveniently be used as input to the CT simulation tool CatSim. (CatSim is also compatible with NURBS-based representations and polygonal phantoms but these were not used here). For this study, the calcifications were all defined as pure calcium.

**CT scanner simulation** – A Lightspeed VCT scanner model in our CT simulation toolkit CatSim [15] is used to perform two sets of virtual CT scans: one set of the patient images and one set of the virtual calcifications. Unlike the clinical image (which already has all the physics effects of the real CT scan), the calcification needs to be simulated with realistic geometric blur effects related to finite focal spot, finite detector size, and rotation (azimuthal) blur. The distance-driven projector was used, which inherently accounts for finite detector size. We performed an over-sampling study to optimize the number focal spot samples, and the number of view samples for computational efficiency.

The patient sinograms are combined with the calcium sinograms and reconstructed, resulting in virtual clinical images *with* blooming artifacts. The patient sinograms are also reconstructed separately and subsequently combined with a voxelized version of the calcification, resulting in clinical images *without* blooming artifacts.

One limitation of this study is that summing patient and calcium sinograms ignores any non-linear spectral effects. This was done for simplicity and we concluded it is justified since the calcifications are small perturbations, which we have previously shown to cause minimal beam hardening impact. In future work, we will incorporate joint simulation of patient and calcifications. Figure 4 shows the example results of virtual images with and without blooming artifacts.

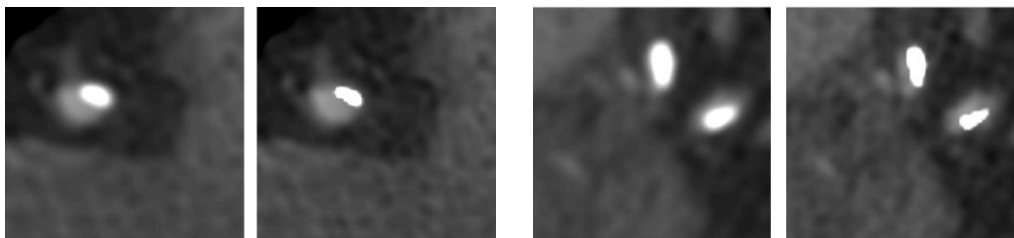


Figure 4. Examples of virtual calcified coronary artery images with (left) and without (right) blooming artifacts.

The VCT framework was used to investigate the impact on calcium blooming of three parameters: X-ray tube voltage (kVp), reconstruction kernel, and focal spot size. The following table shows the parameters that were used in the VCT study:

Tube voltage/spectrum	70 keV (mono) 80 kVp 140 kVp
Focal spot size	1.2 mm 0.6 mm
Reconstruction kernel	Standard Detail Bone Edge
Source-to-iso	541 mm
Source-to-detector	949 mm
Detector cell size	1.02 mm x 1.09 mm
Focal spot sub-sampling	3 x 9
View sub-sampling	3

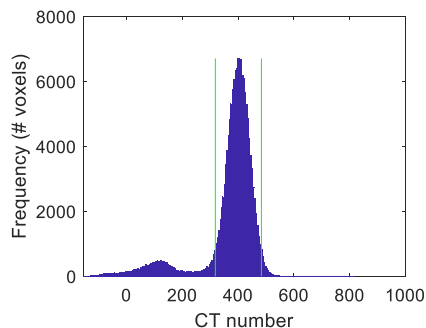


Figure 5. Histogram of CT numbers in a region around the aorta. The aorta CT number is estimated as the average of the peak around 400.

as the average of the peak around 400.

A total of 14 CT exams were used and combined with separate simulations of 130 embedded virtual calcifications. The CT images were acquired by Dr Pontone and the Centro Cardiologico Monzino (University of Milan, Italy) using a Revolution CT scanner (GE Healthcare, Waukesha, WI). Calcifications were detected in both the recon images and the ground truth images using the following automated approach. First a coronary artery mask is computed using a 3D segmentation tool. Second, calcifications are found based on a CT number threshold and a connected-volume threshold (optimized to be robust for image noise).

The calcium segmentation threshold was derived from the average iodine value in the aorta:

$$\text{calcium threshold} = \text{avg. iodine at aorta} - 25$$

The average iodine value at aorta region is obtained by 1) identifying a volume of interest around aorta; 2) computing the CT number (in HU) histogram for the volume of interest; 3) computing the average CT number of the histogram peak. Figure 5 shows a typical histogram of an aorta region. The green lines are the standard deviation of the iodine values around aorta.

### III. RESULTS

Figures 6 and 7 summarize the experimental results. They show the average (over 130 calcifications) percent increase of calcium volume due to blooming for different scan parameters:

$$\text{avg. \% volume change} = \frac{(\text{calcium volume after recon} - \text{GT calcium volume})}{\text{ground truth (GT) calcium volume}}$$

The insets show corresponding images for one example calcification. Figure 6 shows the impact of tube voltage or standard recon kernel and a 1.2 mm focal spot size. Figure 7 shows the impact of reconstruction kernel (standard, detail, bone, edge) and focal spot size (1.2 mm and 0.6 mm) for a monochromatic 70 keV spectrum.

Figure 6 shows that higher kVp helps reduce the calcium blooming effect. For example, the average percent volume change is approximately 36% when using 140kVp for a cardiac CT scan and the calcium volume change increases to 68% when using 80 kVp.

Figure 7 shows that sharper reconstruction kernels (bone, edge) substantially reduce blooming artifacts, although at the expense of increase noise or aliasing artifacts. Reducing the focal spot size has minimal effect when combined with the lower-resolution standard kernel, and results in a small additional improvement when combined with the higher-resolution bone kernel.

While our results show that both kVp and reconstruction kernel have a significant impact on the degree of calcium blooming, it is important to note that in this study we did not adjust the threshold based on the inherent intensity change for calcium at the different kVps. As a result, it is possible that these results have exaggerated the impact of kVp on calcium blooming. In other words, the reduced apparent blooming one achieves by using a higher kVp might just as well be accomplished by using a wider HU window setting in reviewing the images. Further study is needed to assess this in more detail.

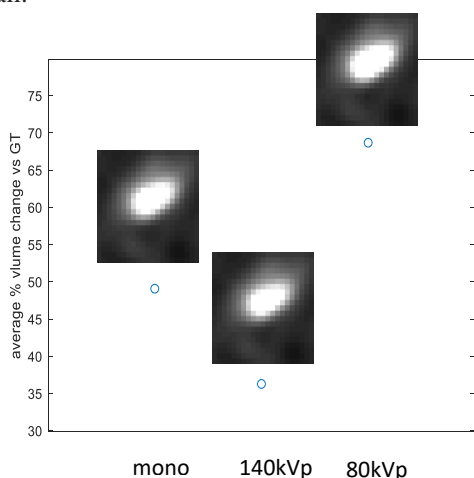


Figure 6. Impact of X-ray tube voltage/spectrum on calcium volume increase due to blooming (in %).

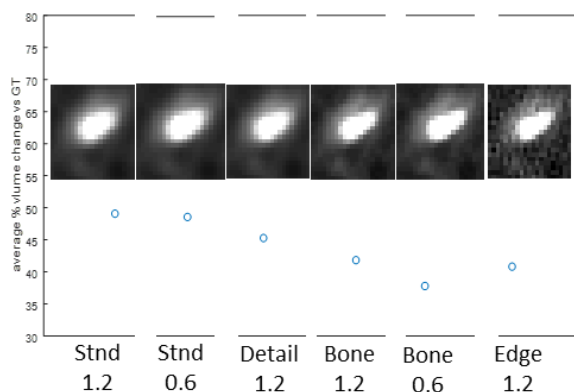


Figure 7. Impact of reconstruction kernel and focal spot size on calcium volume increase due to blooming (in %).

#### IV. CONCLUSION

A VCT framework is developed to evaluate calcium blooming as a function of CT scan and reconstruction parameters. An overview of the VCT framework is presented, as well as a study to explore the relative impact of X-ray tube voltage, reconstruction kernel, and focal spot size on calcium blooming severity. We conclude that:

- X-ray tube voltage/spectrum and reconstruction kernel have significant impact on calcium blooming
- Focal spot size is not the limiting factor and only has an impact when combined with a high-resolution reconstruction kernel.
- Calcification segmentation strongly depends on the threshold and could be greatly improved by tuning threshold settings as a function of scan and reconstruction parameters. This is a complex dependency and requires a more dedicated investigation.

In future work, the current study can be refined by using a more realistic range of calcification compositions and by jointly simulating patient and calcifications. Another next step is to work with clinical experts to evaluate the images under various parameter settings and the practical impact on stenosis assessment.

#### ACKNOWLEDGEMENTS

We would like to thank Dr Pontone and the Centro Cardiologico Monzino (University of Milan, Italy) for supplying cardiac CT image datasets used in this study.

Research reported in this publication was supported by the NIH/NHLBI grant R01HL151561. The content is solely the responsibility of the authors and does not necessarily represent the official views of the NIH.

#### REFERENCES

1. Latina, J., Shabani, M., Kapoor, K., Whelton, S.P., Trost, J.C., Sesso, J., Demehri, S., Mahesh, M., Lima, J.A. and Arbab-Zadeh, A., 2021. Ultra-high-resolution coronary CT angiography for assessment of patients with severe coronary artery calcification: initial experience. *Radiology: Cardiothoracic Imaging*, 3(4), p.e210053.
2. Fuchs A, Köhl JT, Chen MY, Viladés Medel D, Alomar X, Shanbhag SM, Helqvist S, Kofoed KF. Subtraction CT angiography improves evaluation of significant coronary artery disease in patients with severe calcifications or stents—the C-Sub 320 multicenter trial. *Eur Radiol*. 2018;28:4077–4085.
3. Steckmann, S., and M. Kachelries. "Blooming Artifact Reduction for Cardiac CT." IEEE Nuclear Science Symposium & Medical Imaging Conference, 2010. doi:10.1109/nssmic.2010.5874133.
4. Li, Ping, Lei Xu, Lin Yang, Rui Wang, Jiang Hsieh, Zhonghua Sun, Zhanming Fan, and Jonathon A. Leipsic. "Blooming Artifact Reduction in Coronary Artery Calcification by A New Deblooming Algorithm: Initial Study." *Scientific Reports* 8, no. 1 (2018). doi:10.1038/s41598-018-25352-5.
5. Matthias Renker, John W. Nance, Jr, U. Joseph Schoepf, Terrence X. O'Brien, Peter L. Zwerner, Mathias Meyer, J. Matthias Kerl, Ralf W. Bauer, Christian Fink, Thomas J. Vogl, and Thomas Henzler, "Evaluation of Heavily Calcified Vessels with Coronary CT Angiography: Comparison of Iterative and Filtered Back Projection Image Reconstruction" *Radiology* 2011 260:2, 390-399
6. Yan, Siming, Feng Shi, Yuhua Chen, Damini Dey, Sang-Eun Lee, Hyuk-Jae Chang, Debiao Li, and Yibin Xie. "Calcium Removal from Cardiac Ct Images Using Deep Convolutional Neural Network." 2018 IEEE 15th International Symposium on Biomedical Imaging (ISBI 2018), 2018. doi:10.1109/isbi.2018.8363617.
7. Samei, E., Abadi, E., Kapadia, A., Lo, J., Mazurowski, M. and Segars, P., 2020, March. Virtual imaging trials: an emerging experimental paradigm in imaging research and practice. In *Medical Imaging 2020: Physics of Medical Imaging* (Vol. 11312, p. 113121T). International Society for Optics and Photonics.
8. Abadi, E., Segars, W.P., Tsui, B.M., Kinahan, P.E., Bottenus, N., Frangi, A.F., Maidment, A., Lo, J. and Samei, E., 2020. Virtual clinical trials in medical imaging: a review. *Journal of Medical Imaging*, 7(4), p.042805.
9. Hoffmann, Udo, Maros Ferencik, Ricardo C. Cury, and Antonio J. Pena. "Coronary CT Angiography." *The Journal of Nuclear Medicine*, March 13, 2006. Accessed April 23, 2019.
10. Kalisz, Kevin, Ji Bueth, Sachin S. Saboo, and Suhny Abbara. "Artifacts at Cardiac CT: Physics and Solutions." *RadioGraphics*36, no. 7 (October 21, 2016). Accessed April 23, 2019
11. Zhuangli Liang, Karl W. Clem, Do Synho, Brady Thomas, and Pien Homer. "Analysis and Mitigation of Calcium Artifacts in Cardiac Multidetector CT", IEEE ISBI, 2008.
12. Barrett, Julia F., and Nicholas Keat. "Artifacts in CT: Recognition and Avoidance." *RadioGraphics*24, no. 6 (2004): 1679-691. doi:10.1148/rg.246045065.
13. Fihn SD, Gardin JM, Abrams J, Berra K, Blankenship JC, Dallas AP, Douglas PS, Foody JM, Gerber TC, Hinderliter AL, King SB, Kligfield PD, Krumholz HM, Kwong RYK, Lim MJ, Linderbaum JA, Mack MJ, Munger MA, Prager RL, Sabik JF, Shaw LJ, Sikkema JD, Smith CR, Smith SC, Spertus JA, Williams SV, American College of Cardiology Foundation, American Heart Association Task Force on Practice Guidelines, American College of Physicians, American Association for Thoracic Surgery, Preventive Cardiovascular Nurses Association, Society for Cardiovascular Angiography and Interventions, Society of Thoracic Surgeons. 2012 ACCF/AHA/ACP/AATS/PCNA/SCAI/STS Guideline for the diagnosis and management of patients with stable ischemic heart disease: a report of the American College of Cardiology Foundation/American Heart Association Task Force on Practice Guidelines, and the American College of Physicians, American Association for Thoracic Surgery, Preventive Cardiovascular Nurses Association, Society for Cardiovascular Angiography and Interventions, and Society of Thoracic Surgeons. *J Am Coll Cardiol*. 2012;60:e44–e164.
14. Skinner JS, Smeeth L, Kendall JM, Adams PC, Timmis A. NICE guidance. Chest pain of recent onset: assessment and diagnosis of recent onset chest pain or discomfort of suspected cardiac origin. *Heart*. 2010;96:974–978.
15. B. De Man, S. Basu, N. Chandra, B. Dunham, P. Edic, M. Iatrou, S. McOlash, P. Sainath, C. Shaughnessy, and B. Tower, "CatSim: a new computer assisted tomography simulation environment," *Proc. SPIE 6510, Medical Imaging 2007: Physics of Medical Imaging*, vol. 6510, pp. 65102G, 2007.